

# Current Concepts in the Pathogenesis of Age-Related Macular Degeneration

Marco A. Zarbin, MD, PhD

**Objective:** To review and synthesize information concerning the pathogenesis of age-related macular degeneration (AMD).

**Methods:** Review of the English-language literature.

**Results:** Five concepts relevant to the cell biology of AMD are as follows: (1) AMD involves aging changes plus additional pathological changes (ie, AMD is not just an aging change); (2) in aging and AMD, oxidative stress causes retinal pigment epithelial (RPE) and, possibly, choriocapillaris injury; (3) in AMD (and perhaps in aging), RPE and, possibly, choriocapillaris injury results in a chronic inflammatory response within the Bruch membrane and the choroid; (4) in AMD, RPE and, possibly, choriocapillaris injury and inflammation lead to formation of an abnormal extracellular matrix (ECM), which causes altered diffusion of nutrients to the retina and RPE, possibly precipitating further RPE and retinal damage; and (5) the abnormal ECM results in altered RPE-

choriocapillaris behavior leading ultimately to atrophy of the retina, RPE, and choriocapillaris and/or choroidal new vessel growth. In this sequence of events, both the environment and multiple genes can alter a patient's susceptibility to AMD. Implicit in this characterization of AMD pathogenesis is the concept that there is linear progression from one stage of the disease to the next. This assumption may be incorrect, and different biochemical pathways leading to geographic atrophy and/or choroidal new vessels may operate simultaneously.

**Conclusions:** Better knowledge of AMD cell biology will lead to better treatments for AMD at all stages of the disease. Many unanswered questions regarding AMD pathogenesis remain. Multiple animal models and in vitro models of specific aspects of AMD are needed to make rapid progress in developing effective therapies for different stages of the disease.

*Arch Ophthalmol.* 2004;122:598-614

**A**GE-RELATED MACULAR DEGENERATION (AMD) is the leading cause of blindness and visual disability in patients 60 years or older in the Western hemisphere.<sup>1</sup> The clinical presentation of AMD includes drusen, hyperplasia of the retinal pigment epithelium (RPE), geographic atrophy, and choroidal new vessels (CNVs).<sup>2</sup> Only approximately 10% to 15% of patients with AMD have severe central vision loss. Atrophic AMD, characterized by outer retinal and RPE atrophy and subjacent choriocapillaris degeneration, accounts for approximately 25% of cases with severe central vision loss.<sup>1</sup> Exudative AMD is characterized by CNV growth under the RPE and retina, with subsequent hemorrhage, exudative retinal detachment, disciform scarring, and retinal atrophy. Serous or hemorrhagic pigment epithelial detachment also occurs. Exudative AMD accounts for approximately 75% of cases with severe central vision loss.<sup>1</sup> Most

patients with subfoveal choroidal neovascularization develop profound central vision loss regardless of whether the CNV has classic or occult morphologic features on angiography.<sup>3,4</sup> Rarely, patients have peripheral and central vision loss due to extensive subretinal and vitreous hemorrhage.

The prevalence of early AMD (ie, the presence of soft indistinct or reticular drusen or drusen with RPE degeneration or hyperpigmentation) is 18% in the population aged 65 to 74 years and 30% in the population older than 74 years.<sup>5</sup> Findings from 2 population-based studies<sup>6,7</sup> indicate that the prevalence of geographic atrophy is 3.5% in persons older than 75 years, or approximately half the prevalence of CNVs. Since the population older than 65 years is the fastest growing segment of our society, the burden of disease will increase during the 21st century.<sup>8</sup> Considering the high social and financial cost of this problem, the need for new therapies to prevent and treat exu-

*From the Institute of Ophthalmology and Visual Science at the New Jersey Medical School, University of Medicine and Dentistry of New Jersey, Newark. The author has no relevant financial interest in this article.*

dativ and atrophic maculopathy is pressing. Many different strategies are being pursued, ranging from anti-angiogenic therapy to transplantation surgery. The purpose of this review is to summarize recently developed experimental and clinical biological data relevant to the pathogenesis of AMD.

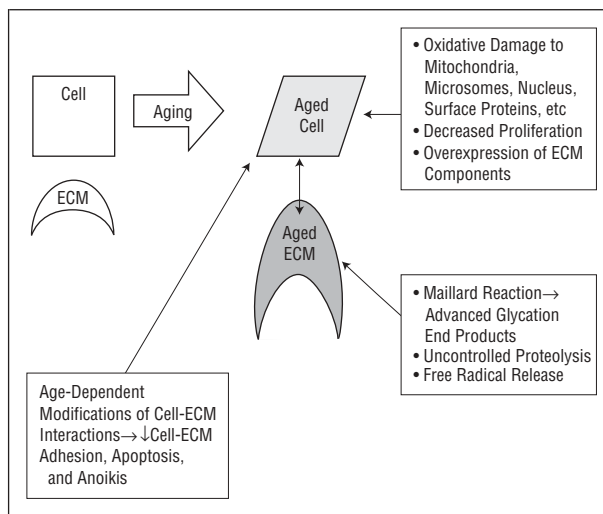
## AGING VS AMD

Aging is associated with biological changes in the eye. These features of aging are present in AMD eyes and may contribute to the pathogenesis of AMD, but they do not lead inevitably to AMD. Thus, it is important to recognize aging changes in the RPE–Bruch membrane–choriocapillaris complex that occur in aged eyes without AMD.

In general, aging is associated with cumulative oxidative injury.<sup>9</sup> For example, postmitotic cells such as RPE cells accumulate mitochondrial DNA deletions and rearrangements with aging.<sup>10</sup> Verzar<sup>11</sup> recognized that aging is associated with extracellular matrix (ECM) alterations. These may include abnormalities of ECM biosynthesis; postsynthetic modifications of ECM, including degradation; altered interaction among ECM components; and changes in cell-ECM adhesion.<sup>12</sup> Aged human fibroblasts, for example, seem to produce structurally and functionally abnormal fibronectin that exhibits reduced binding to native types I and II collagen.<sup>13</sup> Changes in the extracellular environment can induce changes in the cell phenotype.<sup>12</sup> Many of these changes may be under genetic control. Fibroblasts from patients with Werner syndrome, for example, exhibit each of these abnormalities.<sup>14–16</sup> (Werner syndrome is a condition associated with premature aging that results from a loss of function mutations in the *WRN* gene [which encodes a DNA helicase], which leads to rapid telomere shortening.<sup>17</sup>) Epigenetic reactions involved in aging include the Maillard reaction, uncontrolled proteolytic degradation, and free radical release. The Maillard reaction is the reaction of free reducing sugars or reactive aldehydes with free amino groups to form Schiff bases and, after Amadori rearrangements, polycyclic advanced glycation end products.<sup>18</sup> Advanced glycation end products induce cell injury (directly or through cell surface receptors) and can induce dysregulation of tissue remodeling with enhanced deposition of ECM. Each of these features of aging is relevant when considering the aging of the retina–RPE–Bruch membrane–choriocapillaris complex and the pathogenesis of AMD (**Figure 1**).

### RPE Lipofuscin

Lipofuscin comprises a group of autofluorescent lipid-protein aggregates present in nonneuronal and neuronal tissues. As is the case for many postmitotic cells, lipofuscin accumulates in RPE cells during life. In one study,<sup>19</sup> lipofuscin occupied 1% of the RPE cytoplasmic volume during the first decade of life and 19% of the cytoplasmic volume by age 80 years. Reduction in functional cytoplasmic volume might compromise RPE function, for example, phagocytosis,<sup>20</sup> which can lead to photoreceptor death. In the RPE, the major source of li-



**Figure 1.** Effects of aging on cells and the extracellular matrix (ECM). Oxidative damage results in altered cell behavior, including decreased proliferation and overexpression of ECM components. Abnormal cell-ECM interactions result in programmed cell death (apoptosis), including death initiated by separation of the cell from its basement membrane (anoikis).

pofuscin is the undegradable products of photoreceptor outer segment metabolism.<sup>21</sup> Intralysosomal iron-catalyzed reactions generate lipofuscin. By producing reactive oxygen species, lipofuscin may induce oxidative damage in the RPE and surrounding tissues and may inhibit RPE lysosomal enzyme activity (see the bulleted list). Okubo and coworkers<sup>22</sup> found a linear relationship between RPE autofluorescence and Bruch membrane thickness, which indicates that aging changes in the RPE and Bruch membrane may be related.

### Bruch Membrane Thickness

Bruch membrane thickness seems to increase linearly with aging from approximately 2  $\mu\text{m}$  at birth to approximately 4 to 6  $\mu\text{m}$  in the tenth decade of life.<sup>23</sup> Bruch membrane thickening can arise from increased production and decreased degradation of extracellular material. As noted in the “Bruch Membrane Composition and Permeability” subsection, changes in thickness are associated with changes in protein composition, protein cross-linking, increased glycosaminoglycan size, and increased lipid content. Age-related thickening of the Bruch membrane is not confined to the inner collagenous layer. For example, native Bruch membrane collagen content increases in the outer collagenous layer during the teens. By age 40 years, wide-spaced collagen also accumulates in this layer.<sup>24</sup> Periodic acid–Schiff–positive material that resembles the contents of RPE phagosomes accumulates in the inner collagenous layer and, later, in the elastic layer.<sup>25</sup> Thus, during aging, dysfunctional RPE cells might produce abnormal quantities of ECM material, including cell fragments, collagen, and other basement membrane components.<sup>26,27</sup>

Impaired ability to degrade the ECM might contribute to age-related Bruch membrane thickening. Matrix metalloproteinases (MMPs), for example, are zinc-dependent enzymes that catabolize ECM proteins, including collagen and elastin. Tissue inhibitors of metal-

**Table 1. Distribution of Various Extracellular Matrix Molecules in the Human Bruch Membrane<sup>37,38</sup>**

Bruch Membrane Lamina	Extracellular Matrix Molecule
RPE basement membrane	Types IV and V collagen; laminin; heparan sulfate
Inner collagenous layer	Types I, III, and V collagen; fibronectin; chondroitin sulfate; dermatan sulfate
Elastic lamina	$\alpha$ -Elastin; type VI collagen; fibronectin
Outer collagenous layer	Types I, III, and V collagen; fibronectin; chondroitin sulfate; dermatan sulfate
Choriocapillaris basement membrane	Types IV, V, and VI collagen; laminin; heparan sulfate

Abbreviation: RPE, retinal pigment epithelium.

loproteinases (TIMPs) regulate the activity of MMPs. Retinal pigment epithelium cells produce MMPs and TIMP-3.<sup>28-30</sup> Inactive forms of MMP-2 and MMP-9 increase in the Bruch membrane with aging, particularly in the submacular Bruch membrane.<sup>31</sup> Abnormalities in metalloproteinase activity can result in changes in Bruch membrane thickness. Mutations of TIMP-3, for example, can cause decreased TIMP-3 turnover and result in Sorsby fundus dystrophy, a condition characterized by the accumulation of abnormal extracellular material between the RPE and the inner collagenous layer of the Bruch membrane.<sup>32,33</sup> Bruch membrane TIMP-3 content increases with age.<sup>34</sup> Since TIMP-3 gene expression in the macular area does not increase substantially with aging,<sup>35</sup> there may be altered TIMP-3 turnover with sustained MMP inhibition during aging.

Age-related declines in choriocapillaris density and lumen diameter (see the "Choroidal Blood Flow" subsection) might also decrease clearance of debris from the Bruch membrane, which would contribute to thickening with age. In Sorsby fundus dystrophy, symptoms and retinal function improve with high-dose vitamin A therapy, suggesting that impaired diffusion across the Bruch membrane can be a consequence of Bruch membrane thickening.<sup>36</sup> (The material that accumulates in the Bruch membrane in this condition resembles the abnormal extracellular debris deposited in the Bruch membrane in AMD.)

### Bruch Membrane Composition and Permeability

Various collagens, glycosaminoglycans, laminin, and fibronectin are normal constituents of the Bruch membrane (**Table 1**). With aging, the Bruch membrane thickens, periodic acid-Schiff staining increases, and Bruch membrane type I collagen increases.<sup>26,35,39-42</sup> Membranous debris, filamentous material, and coated vesicles accumulate primarily in the inner collagenous layer by early adulthood and continue to do so throughout adult life.<sup>39</sup> With aging, collagen cross-linking seems to increase in the Bruch membrane, and there is a significant increase in the amount of noncollagen protein in the submacular Bruch membrane but not in the periphery, which might mean that protein-containing debris is trapped in the Bruch membrane during aging.<sup>43</sup> By late middle age, lipid

deposition in the Bruch membrane is apparent.<sup>39</sup> Basal laminar deposit, which comprises mostly wide-spaced collagen<sup>40</sup> and other materials, including laminin, membrane-bound vesicles, and fibronectin, is present in the seventh decade of life during normal aging.<sup>44-46</sup> Pauleikhoff and coworkers<sup>47</sup> reported an age-related decline in the presence of laminin, fibronectin, and type IV collagen in the RPE basement membrane (especially over drusen). Basal linear deposit, consisting primarily of granular and vesicular material with foci of wide-spaced collagen, appears in older persons and is more specific for AMD.<sup>44,48</sup> During aging, Bruch membrane glycosaminoglycans increase in size, and heparan sulfate content increases.<sup>38</sup> Advanced glycation end products accumulate in the Bruch membrane during aging.<sup>49</sup> Advanced glycation end products have been shown to promote trapping of macromolecules,<sup>50,51</sup> and they might alter cellular trafficking through the Bruch membrane, particularly if the cells express receptors for advanced glycation end products. Molecules present in the Bruch membrane impart a negative electrostatic charge at physiologic pH.<sup>38,52</sup> Age-related changes in glycosaminoglycans might alter this charge and, as a result, the permeability properties of the Bruch membrane.<sup>38</sup>

Thus, the molecular composition of the Bruch membrane and the tight junctions between RPE cells affect the movement of molecules between the choriocapillaris and the subretinal space. Most evidence indicates that the hydraulic conductivity of the Bruch membrane decreases exponentially with age in healthy individuals.<sup>41,53</sup> At any given age, the submacular Bruch membrane is affected to a greater degree than the peripheral Bruch membrane. Starita and coworkers<sup>42</sup> used excimer laser ablation of different layers of the Bruch membrane to demonstrate that most of the resistance to water flow lies in the inner collagenous layer of the Bruch membrane. These investigators suggested that a high-resistance barrier develops in the Bruch membrane in older eyes, probably due to lipid and vesicular-granular debris entrapment in the Bruch membrane.

Most of the Bruch membrane hydraulic conductivity decrease occurs by age 40 years. Marshall and coworkers<sup>39</sup> noted the discrepancy between the early rapid decline in conductivity and the relatively slower rate of increase in Bruch membrane thickness. Age-related changes in Bruch membrane biochemical composition probably underlie the discrepancy. Specifically, there is increased lipidization, protein cross-linking, and protein deposition in the Bruch membrane with aging. Lipid accumulation in the Bruch membrane begins to increase substantially after age 40 years.<sup>54,55</sup> The rate of lipid accumulation under the macula may be higher than under the peripheral retina, perhaps due to the greater density of photoreceptors in the macula and a greater susceptibility of outer segment lipids to peroxidation in the posterior pole. Spaide and coworkers<sup>56</sup> found that the amount of peroxidized lipids in the Bruch membrane increased exponentially with age. The lipids seemed to be derived from long-chain polyunsaturated fatty acids normally found in the outer segments, for example, docosahexanoic acid and linoleic acid, providing support for the notion that at least some of the lipid in the Bruch mem-

brane is of cellular origin rather than derived from the blood.

Bruch membrane morphometry indicates that the elastin layer has the highest porosity and that the inner collagenous layer has the lowest porosity.<sup>39</sup> The elastin layer seems to become increasingly porous with age.<sup>57</sup> This layer might normally constitute a barrier to vessel growth between the choroid and the sub-RPE space, and this age-related change might have a permissive effect on CNV growth. Marshall and coworkers<sup>39</sup> proposed that from the late teens to the late thirties, membranous debris, vesicles, and collagen accumulation cause a reduction in effective pore size in the inner collagenous layer. From the forties to the sixties, this process continues, and, abetted by substantial lipid deposition, there is an accelerated decline in hydraulic conductivity. At older ages, the deposition of basal laminar and linear deposit further reduces functional pore size. In older persons, diffusion of small and large molecules across the Bruch membrane is impaired.<sup>58-60</sup> Changes in protein cross-linking, non-collagenous protein deposition, and age-related lipid accumulation in the Bruch membrane may be the underlying cause.<sup>61</sup> To the degree that hydrodynamic forces alter molecular transport across the Bruch membrane, it seems possible that hypertension would exacerbate age-related trans-Bruch membrane transport problems.

### Choroidal Blood Flow

Changes in choroidal blood flow in aging and AMD have been reviewed by Luty and coworkers.<sup>62</sup> Ramrattan and coworkers<sup>23</sup> showed that there is a progressive decrease in the thickness of the choroid from 200  $\mu\text{m}$  at birth to 80  $\mu\text{m}$  by age 90 years. The choriocapillaris density and lumen diameter decrease, and the width of the intercapillary pillars increases with age.<sup>23,63</sup> In view of these histologic changes, it is not surprising that subfoveal choroidal blood flow decreases with age.<sup>64</sup> Indocyanine green choriocapillaris filling, for example, is delayed in persons older than 50 years, and areas of hypofluorescence are present in the macula of patients with AMD. Laser Doppler flowmetry of the submacular choriocapillaris demonstrates decreased choroidal blood flow and volume in individuals older than 46 years, with further reduction in patients with AMD. Guymer and coworkers<sup>65</sup> pointed out that if choriocapillary endothelial cell processes, which are present in the Bruch membrane, play a role in clearing debris from the Bruch membrane, then an age-related loss of choriocapillaries could play a causal role in Bruch membrane thickening during aging. Alternatively, as the RPE produces substances that help maintain normal choriocapillary density and anatomy,<sup>66</sup> Bruch membrane thickening might cause age-related choriocapillary changes by impairing diffusion of these substances to the choriocapillaris.

### Aging and Oxidative Stress

Aging is associated with increased oxidative damage.<sup>9,67</sup> Plasma glutathione levels decrease, and oxidized glutathione levels increase, for example, with age.<sup>68</sup> Plasma levels of vitamin C and vitamin E also decrease with

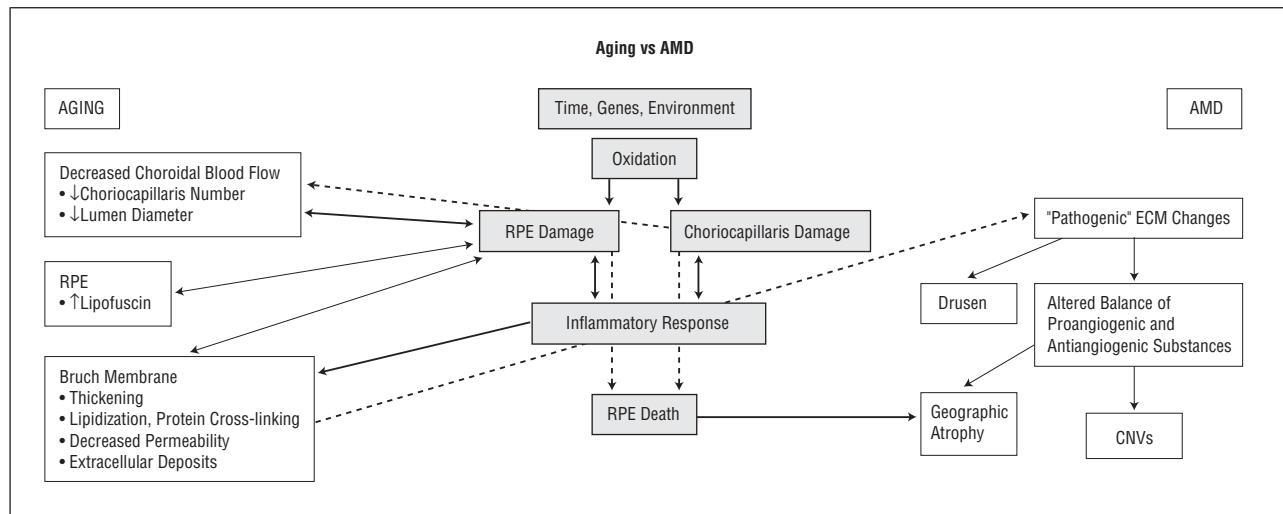
age.<sup>69,70</sup> Lipid peroxidation seems to increase with aging.<sup>71,72</sup> The susceptibility of RPE cells to oxidative damage increases with aging. For example, RPE cell vitamin E levels and catalase activity decrease with aging.<sup>73,74</sup> Macular pigment optical density decreases with aging.<sup>75</sup> Retinal pigment epithelium cell lipofuscin content, which enhances susceptibility to oxidative damage, increases with aging. In addition, RPE cells that experience phototoxicity exhibit membrane blebbing,<sup>76</sup> a phenomenon observed in aging and AMD eyes (see the "Evidence of Oxidative Damage in AMD" and "Inflammation" subsections). One study<sup>77</sup> reported that RPE density decreases approximately 0.3% per year throughout life.

Oxidative damage to the RPE is a potential final common pathway for age-related retinal damage that depends on genetic predisposition, cumulative light damage, free radical injury, and hemodynamic abnormalities (reviewed by Winkler,<sup>78</sup> Beatty,<sup>75</sup> and Cai<sup>79</sup> and their colleagues). Production of reactive oxygen species is stimulated by irradiation, aging, inflammation, increased partial pressure of oxygen, air pollutants, cigarette smoke, and reperfusion injury. Oxygen-derived metabolites cause oxidative damage to cytoplasmic and nuclear elements of cells and cause changes in the ECM. Reactive oxygen species react, for example, with nucleic acids, membrane lipids, surface proteins, and integral glycoproteins.

Beatty and coworkers<sup>75</sup> reviewed the factors promoting reactive oxygen species formation in the retina and RPE:

- Outer segments are enriched in polyunsaturated fatty acids
- Oxygen tension in the photoreceptor-RPE area is close to that of arterial blood
- The retina is exposed to high levels of cumulative irradiation
- The retina and RPE contain photosensitizers: rhodopsin, lipofuscin, and cytochrome *c* oxidase
- The choriocapillaris contains blood-borne photosensitizers
- RPE phagocytosis is an oxidative stress

Briefly, photoreceptor outer segments are enriched in polyunsaturated fatty acids, which can undergo lipid peroxidation. Lipid peroxidation is greatest in the macula and increases with age.<sup>80</sup> In vitro evidence<sup>20,81,82</sup> indicates that RPE lipofuscin is a photoinducible generator of reactive oxygen species that can compromise lysosomal integrity, induce lipid peroxidation, reduce phagocytic capacity, and cause RPE cell death. Lipofuscin granules are continuously exposed to visible light and high oxygen tension, which cause reactive oxygen species production and possibly further oxidative damage to the RPE cell proteins and lipid membranes.<sup>78,83</sup> Retinal pigment epithelium lipofuscin is derived in part from vitamin A metabolites and lipid peroxides.<sup>84</sup> (Vitamin A is a major constituent of photoreceptor outer segments.) The reaction product of ethanolamine and 2 retinaldehyde molecules, *N*-retinylidene-*N*-retinylethanolamine (A2-E), is the major photosensitizing chromophore in lipofuscin that causes reactive oxygen species production; A2-E also raises lysosomal pH, thus interfering with lysosomal en-



**Figure 2.** Aging vs age-related macular degeneration (AMD). RPE indicates retinal pigment epithelium; ECM, extracellular matrix; CNV, choroidal new vessel.

zyme activity and reducing lysosomal protein and glycosaminoglycan degradation.<sup>82,85,86</sup> When RPE cells are exposed to light, A2-E conjugated to low-density lipoprotein, which accumulates in RPE lysosomes, causes loss of lysosomal integrity<sup>82</sup>; A2-E also inhibits RPE phagolysosomal degradation of photoreceptor phospholipid *in vitro*.<sup>87</sup> Retinal pigment epithelium cells with excessive A2-E exhibit membrane blebbing and extrusion of cytoplasmic material into the Bruch membrane.

### Aging-AMD Overlap

One biochemical study<sup>88</sup> of drusen composition found that up to 65% of the proteins identified in drusen are present in drusen derived from AMD as well as healthy age-matched donors. Approximately 33% of the drusen-derived proteins from AMD donors were not observed in healthy donor drusen. These findings may mean that although there is some degree of continuity between aging changes in the Bruch membrane and aging changes associated with AMD, there also are distinct differences. For example, in this study, docosahexaenoate lipid-derived oxidative modifications were much more common in AMD eyes than in age-matched control eyes. Docosahexanoic acid is a highly unsaturated fatty acid that makes up approximately 50% of rod phospholipids.

### PATHOGENESIS OF AMD

One model of aging vs AMD consistent with published clinical, pathological, and experimental observations is shown in **Figure 2**. Age-related macular degeneration involves aging changes plus additional pathological changes. In AMD and aging, oxidative stress results in RPE and, possibly, choriocapillaris injury. In AMD, and possibly in aging, RPE injury elicits an inflammatory response in the Bruch membrane and the choroid. In AMD eyes, RPE injury and inflammation foster the production of an abnormal ECM derived largely from the RPE and photoreceptor cells but also from cells in the choroid and from substances in the systemic circulation. The abnormal ECM, in turn, results in altered RPE biologic

behavior and may cause further damage to the retina, RPE, and choroid. Oxidative damage to the choriocapillaris also may contribute to the pathogenesis of AMD. The factors mediating CNV growth and the development of geographic atrophy involve perturbation of RPE-choriocapillaris homeostasis. Retinal pigment epithelium death, for example, probably is the cause of choriocapillaris loss in geographic atrophy.<sup>66,89</sup> Evidence for the pathogenic role of oxidative stress, inflammation, ECM abnormalities, altered RPE biologic behavior, and genetics is considered in the following subsections.

### Evidence of Oxidative Damage in AMD

**Clinical Studies of Antioxidants.** The Age-Related Eye Disease Study,<sup>90</sup> a multicenter randomized clinical trial involving more than 3600 patients, demonstrated that among patients with extensive intermediate drusen, at least 1 large druse, noncentral geographic atrophy in 1 or both eyes, advanced AMD in 1 eye, or vision loss in 1 eye due to AMD, supplementation with antioxidant vitamins (ascorbic acid, 500 mg/d; vitamin E, 400 IU/d; and beta carotene, 15 mg/d) and minerals (zinc oxide, 80 mg/d; cupric oxide, 2 mg/d) reduces the risk of developing advanced AMD from 28% to 20% and the rate of at least moderate vision loss from 29% to 23%. Zinc is essential for the function of some antioxidant enzymes (eg, superoxide dismutase, catalase, and metallothionein) and is the most abundant trace element in human eyes.<sup>91</sup> As noted in the “Bruch Membrane Thickness” subsection, zinc also is important for MMP activity. Results of the Age-Related Eye Disease Study<sup>90</sup> indicate that oxidative damage plays a role in the progression of AMD in its clinically evident intermediate and late stages and that disease progression can be altered with antioxidant supplementation. Earlier trials<sup>68,92-96</sup> of zinc therapy and of dietary zinc intake gave conflicting results, possibly due to small sample size, relatively short follow-up, and/or inadequate dosing.

Other studies<sup>68,92-97</sup> have provided data regarding antioxidant status and the risk of AMD, with conflicting re-

sults in some cases. Complexities of study design (eg, the number of patients studied and reliance on historical information provided by patients), variability in diet-plasma correlation for micronutrients and antioxidants (eg, carotenoids), uncertain relationships between plasma levels of antioxidants and micronutrients and their ocular tissue levels, and the possible importance of interactions between various antioxidants and micronutrients might all underlie the variable results reported in these studies. Other data supporting the hypothesis that oxidative damage plays a role in AMD pathogenesis are as follows.

**Epidemiologic Studies.** Thus far, the most important risk factors for AMD (ie, those associated with at least a 2-fold increased risk) seem to be age, smoking, and race.<sup>6,98-100</sup> Regarding age, the prevalence of late AMD is approximately 0% at 50 years, 2% at 70 years, and 6% at 80 years.<sup>101</sup> The effect of age on risk might indicate that oxidative damage must be gradual and cumulative for AMD to develop. Also, it might be a sign that mitochondrial DNA damage plays a role in the pathogenesis.<sup>102</sup> Smoking depresses antioxidants (eg, decreases plasma vitamin C and carotenoids), induces hypoxia and reactive oxygen species, and alters choroidal blood flow.<sup>103,104</sup> Regarding the effect of race, white patients have a relatively higher risk of large drusen, pigmentary abnormalities, and exudative AMD complications compared with black patients.<sup>44,105,106</sup> Differences in melanin content may underlie, in part, the racial differences in risk of advanced AMD. Melanin is a high-molecular-weight polymer arising from enzymatic oxidation of tyrosine and dihydroxyphenylalanine and is located in melanosomes, which are membrane-bound granules. In vitro experiments indicate that melanin reduces lipofuscin accumulation in RPE cells, possibly by interacting with transition metals and scavenging radicals to function as an antioxidant.<sup>107</sup> The RPE melanin content in white and black patients is similar, but black patients have substantially more choroidal melanin than whites.<sup>108</sup> Perhaps oxidative reactions in the Bruch membrane (see the "Inflammation" subsection) or at the level of the RPE can be attenuated by choroidal melanin. Alternatively, the protective effect of race may mean that the most important oxidative reactions leading to AMD occur at the level of the choriocapillaris.<sup>109</sup> The fact that choriocapillaris density decreases with AMD is consistent with but does not prove this hypothesis (see the "Abnormal ECM" and "Altered RPE-Choriocapillaris Behavior" subsections).<sup>23,89,110</sup>

**Biochemical Studies.** Antioxidants act by preventing the formation of initiating radicals, binding metal ions, and removing damaged molecules. Major antioxidants in the retina and RPE include water-soluble metabolites and enzymes (vitamin C [ascorbic acid], glutathione, catalase, glutathione peroxidase, and superoxide dismutase), lipid-soluble substances (vitamin E [ $\alpha$ -tocopherol], retinoids [vitamin A derivatives], and carotenoids), and melanin.<sup>75,78,79</sup> The antioxidant enzymes, for example, superoxide dismutase, catalase, and glutathione peroxidase, constitute the primary defense against oxidative RPE damage.<sup>111</sup> Antioxidant molecules, for example, ascorbic acid

(vitamin C), tocopherol (vitamin E), and carotenoids, support the enzymatic systems.

The protective mechanisms against oxidative RPE damage seem to decrease with aging, and, in some cases, these changes are greatest in AMD eyes (vs age-matched control eyes). For example, RPE catalase levels decrease with aging and with AMD.<sup>73,112</sup> Metallothionein is an acute-phase reactant protein that scavenges hydroxyl radicals, and there is an age-related decrease in submacular RPE metallothionein content.<sup>113</sup> Plasma glutathione reductase is reduced substantially in patients with AMD.<sup>114</sup> Frank and coworkers<sup>112</sup> found that heme oxygenase-1 and heme oxygenase-2 immunoreactivity tended to decrease with increasing age, especially in RPE lysosomes of neovascular AMD eyes. Oxidative stress probably causes pathologic up-regulation of lysosomal heme oxygenase-1 and possibly heme oxygenase-2. These investigators found that copper-zinc superoxide dismutase immunoreactivity increases in the cytoplasm of submacular RPE in eyes with AMD and CNVs. The Pathologies Oculaires Liées à l'Age Study<sup>115</sup> found that higher plasma levels of glutathione peroxidase were associated with a significantly increased prevalence of late but not early AMD. Beatty and coworkers<sup>75</sup> pointed out that extracellular glutathione peroxidase is believed to act as an extracellular antioxidant, which may be relevant for oxidative reactions occurring in the Bruch membrane and the choriocapillaris (see the "Inflammation" subsection).

Carotenoids, especially lutein and zeaxanthin, compose the macular pigment. The primary direct antioxidant function of carotenoids is to scavenge singlet oxygen, but they also quench the triplet state of photosensitizers and retard the peroxidation of membrane phospholipids.<sup>116,117</sup> Factors associated with increased risk for AMD and increased risk for low macular pigment density include age, cigarette smoking, female sex, light iris color, and increasing lens density,<sup>118-121</sup> but not all clinical studies confirm the association between low macular pigment density and increased risk for AMD.<sup>122</sup> Two postmortem studies<sup>123,124</sup> revealed decreased retinal lutein and zeaxanthin levels in AMD eyes vs control eyes. Increasing age and advanced AMD in the fellow eye have been associated with a relative absence of macular pigment.<sup>125</sup>

Findings from in vitro and in vivo animal studies indicate that basal laminar deposit may form as a result of free radical-induced lipid peroxidation of RPE cell membranes with subsequent membrane blebbing and accumulation of blebs as basal laminar deposit-like material in the sub-RPE space.<sup>126</sup> Advanced glycation end products occur at sites of oxidant stress with hydroxyl radical formation. Advanced glycation end products occur in soft drusen, in basal laminar and basal linear deposits, and in the cell cytoplasm of RPE associated with CNVs.<sup>88,127</sup> When RPE cell lines are grown on a matrix modified by advanced glycation end products, they express genes (eg, transforming growth factor  $\beta_2$ ) that might promote Bruch membrane thickening.<sup>128</sup> Advanced glycation end products induce increased expression of cytokines known to occur in CNVs.<sup>127</sup> Carboxymethyl lysine, a product of lipoprotein peroxidation or sequential oxidation and glycation, is present in drusen and CNVs.<sup>88,129</sup> One study<sup>88</sup>

of drusen protein composition reported oxidative protein modifications in TIMP-3 and vitronectin. Also, carboxyethyl pyrrole protein adducts, which are uniquely generated from the oxidation of docosahexaenoate-containing lipids, were present and were much more abundant in drusen from AMD vs age-matched control donors. (As noted previously herein, docosahexaenoate lipid is abundant in photoreceptor outer segments.) The collocation of lipofuscin-induced autofluorescence and drusen suggests an etiologic relationship between the two, but this collocation has not been observed in all studies.<sup>130,131</sup> Genetic defects (eg, in antioxidant enzymes), dietary or uptake deficiencies in antioxidants, or exposure to noxious agents (eg, cigarette smoking) could enhance oxidative RPE damage during life and predispose to AMD and other signs of aging.

### Inflammation

Anatomic studies<sup>132-135</sup> provided initial evidence for the role of inflammation in CNV formation in AMD. Subsequently, molecular evidence for the role of inflammation in AMD pathogenesis has been developed and summarized by Hageman,<sup>136</sup> Johnson,<sup>137</sup> and Anderson<sup>138</sup> and their coworkers. Protein components of drusen include immunoglobulin and components of the complement pathway associated with immune complex deposition (eg, C5b-9 complex), molecules involved in the acute-phase response to inflammation (eg, amyloid P component and  $\alpha_1$ -antitrypsin), proteins that modulate the immune response (eg, vitronectin, clusterin, apolipoprotein E, membrane cofactor protein, and complement receptor 1), major histocompatibility complex class II antigens, and HLA-DR and cluster differentiation antigens.<sup>139-142</sup> Cellular components of drusen include RPE blebs, lipofuscin, and melanin, as well as choroidal dendritic cells.<sup>136,143-146</sup> Hageman and coworkers<sup>136</sup> postulated that choroidal dendritic cells are activated and recruited by injured RPE (eg, via monocyte chemotactic protein) and oxidized proteins and lipids in the Bruch membrane. A similar process occurs in atherosclerosis. The RPE cells respond to control dendritic cell activation by secreting proteins that modulate the immune response, including vitronectin, apolipoprotein E, and membrane cofactor protein.<sup>137</sup> Johnson and coworkers<sup>137,147</sup> pointed out that the cytoplasmic accumulation of vitronectin, apolipoprotein E, and other drusen-associated molecules suggests that the cells are subjected to a chronic sublethal complement attack. These researchers recognized that complement attack can result in the elimination of surface-associated membrane attack complexes (by shedding or endocytosis of cell membrane) and in the formation of extracellular deposits of immune complexes and complement intermediates. Penfold and coworkers<sup>148</sup> reported an increase in major histocompatibility complex class II immunoreactivity on retinal vascular elements and morphologic changes in microglia in eyes with incipient AMD. These immunologic changes seemed to be related to early pathological changes in RPE pigmentation and drusen formation. Evidence of inflammatory cell involvement in the later stages of AMD includes the presence of multinucleated giant cells and leukocytes in the choroid of AMD

eyes<sup>149-151</sup> and in excised CNVs.<sup>152,153</sup> Macrophages and foreign body giant cells near the Bruch membrane become more common when basal linear deposit is present.<sup>151</sup> Activated macrophages and other inflammatory cells secrete enzymes that can damage cells and degrade the Bruch membrane, and, by releasing cytokines, inflammatory cells might foster CNV growth into the sub-RPE space.<sup>154,155</sup> Thus, in AMD eyes, breaks in the Bruch membrane probably are the result and not the cause of CNVs.<sup>156</sup> In some systems, ECM degradation is associated with free radical release.<sup>157,158</sup>

Poorly degradable RPE debris and Bruch membrane components (eg, wide-spaced collagen) might stimulate chronic inflammation.<sup>27,46,150,159</sup> Hageman and coworkers<sup>136</sup> suggested that activation of choroidal dendritic cells might initiate an autoimmune response to retinal and/or RPE antigens or to neoantigens created within the Bruch membrane. Despite the RPE and retina being immune-privileged tissues,<sup>160</sup> antiretinal and anti-RPE antibodies have been detected in the serum of patients with AMD.<sup>136,161,162</sup> Johnson and coworkers<sup>137</sup> pointed out that complement activation and associated inflammatory events occur in diseases exhibiting cellular degeneration and accumulation of abnormal tissue deposits, for example, atherosclerosis and Alzheimer disease.<sup>163</sup> In these diseases, damaged cells and highly insoluble protein deposits and extracellular debris activate the classical and alternative complement pathways, resulting in chronic direct and bystander cellular damage with attendant cell surface blebbing, endocytosis, and up-regulation of defense proteins. The Alzheimer amyloid  $\beta$  peptide co-localizes with activated complement components in a substructural vesicular component with drusen.<sup>164</sup>

Intravitreal corticosteroids reduce the incidence of laser-induced CNVs in primates, possibly by altering inflammatory cell activity and/or numbers in the choroid.<sup>165</sup> Other potential mechanisms include reduction of vascular endothelial growth factor (VEGF) expression (see the "Biochemical Features of CNV Growth" subsection) and down-regulation of intercellular adhesion molecule 1,<sup>166,167</sup> which is constitutively expressed on RPE and choroidal endothelial cells and mediates leukocyte adhesion and diapedesis during inflammation.<sup>168,169</sup>

### Abnormal ECM

The RPE deposits cytoplasmic material into the Bruch membrane throughout life, possibly to eliminate cytoplasmic debris or as a response to chronic inflammation (see the "Inflammation" subsection).<sup>143,170-172</sup> Histologically, AMD eyes exhibit abnormal extracellular material in 2 locations: (1) between the RPE plasmalemma and the RPE basement membrane and (2) external to the RPE basement membrane within the collagenous layers of the Bruch membrane. The former material is termed *basal laminar deposit*, and the latter material is termed *basal linear deposit*.<sup>44</sup> Although basal laminar deposit persists in areas of geographic atrophy, basal linear deposit disappears, which is consistent with the notion that basal linear deposit arises mostly from the RPE-photoreceptor complex.<sup>173</sup> Basal linear deposit may be more spe-

cific to AMD than basal laminar deposit.<sup>48</sup> Soft drusen can represent focal accentuations of basal laminar deposit in the presence or absence of diffuse basal laminar deposit-associated thickening of the inner aspects of the Bruch membrane.<sup>44,174</sup> Soft drusen can also represent a localized accumulation of basal laminar deposit in an eye with diffuse basal laminar deposit.<sup>174</sup> Thus, the abnormal ECM of AMD eyes includes basal laminar deposit, basal linear deposit, and their clinically evident manifestation, soft drusen.

Drusen represent the earliest clinical finding in AMD. Drusen composition and origin have been analyzed extensively.\* Small (ie, <63- $\mu$ m-diameter) drusen generally do not signify the presence of AMD.<sup>5,26,44,178</sup> Excessive numbers of small hard drusen, however, can predispose to RPE atrophy at a relatively young age.<sup>179</sup> Soft drusen are usually pale yellow and large ( $\geq 63$   $\mu$ m in diameter), with poorly demarcated boundaries. Many different molecules have been identified in drusen, including glycoconjugates<sup>180</sup> containing mannose, sialic acid, N-acetylglucosamine, and  $\beta$ -galactose (**Table 2**). Abnormal constituents of the ECM probably underlie the increased blue-green autofluorescence of the Bruch membrane in AMD eyes.<sup>181</sup>

Most of the molecular constituents of drusen are synthesized by RPE, neural retina, or choroidal cells, but some are derived from extraocular sources.<sup>56,127,136,176,177,182</sup> Several investigators<sup>183,184</sup> have noted that drusen tend to be distributed near the collecting venules of choriocapillaris lobules, which has led to the hypothesis that drusen are derived from the choroidal vasculature. An alternative explanation is that RPE cell susceptibility to metabolic derangement depends, to some degree, on the location of a given cell with respect to the underlying choriocapillaris lobule.

A variety of drusen constituents (eg, vitronectin, apolipoproteins B and E, complement, and lipid) are present in atherosclerotic plaques, which may reflect the association of some atherosclerosis risk factors with the development of AMD. Amyloid P component, C5, and  $\alpha_1$ -antitrypsin are acute-phase reactants (ie, up-regulated expression in response to inflammation), and vitronectin, C5, and apolipoprotein E have roles in mediating immune responses. These findings have led to the suggestion that immune complex-mediated damage to RPE cells plays a role in the initiating events of drusen formation, as noted herein. It may be that terminal complement activation promotes drusen breakdown by enzymatic digestion and phagocytosis.<sup>140</sup> An immune response directed against RPE-derived antigens might be the trigger for drusen formation.

Although MMPs and TIMPs are present in plasma,<sup>185</sup> immunohistochemical studies of MMP and TIMP indicate that at least some MMPs and TIMPs in the Bruch membrane are derived from the RPE (see the "Bruch Membrane Thickness" subsection). Changes in MMPs and their inhibitors indicate that in AMD, RPE dysfunction could result in abnormal MMP activity, which could contribute to the exaggerated development of an abnormal ECM (compared with age-matched controls). For example,

**Table 2. Some Molecular Constituents of Drusen**

$\alpha_1$ -Antichymotrypsin
$\alpha_1$ -Antitrypsin
Alzheimer amyloid $\beta$ peptide
Advanced glycation end products
Amyloid P component
Apolipoproteins B and E
Carbohydrate moieties recognized by wheat germ agglutinin, <i>Limax flavus</i> agglutinin, concanavalin A, <i>Arachis hypogaea</i> agglutinin, and <i>Ricinus communis</i> agglutinin
Cholesterol esters
Clusterin
Complement factors (C1q, C3c, C4, C5, C5b-9 complex)
Cluster differentiation antigen
Complement receptor 1
Factor X
Heparan sulfate proteoglycan
Human leukocyte antigen DR
Immunoglobulin light chains
Major histocompatibility complex class II antigens
Membrane cofactor protein
Peroxidized lipids (derived from long-chain polyunsaturated fatty acids, ie, linolenic acid and docosahexanoic acid, which are usually found in photoreceptor outer segments)
Phospholipids and neutral lipids
Tissue inhibitor of matrix metalloproteinases-3
Transferrin (major carrier of vitamin A in the blood)
Ubiquitin
Vitronectin

TIMP-3 is present in drusen,<sup>34,186</sup> and TIMP-3 levels seem to be increased in drusen and in the Bruch membrane of AMD eyes.<sup>34</sup> Binding of TIMP-3 to advanced glycation end products, which are present in the Bruch membrane and drusen (see the "Role of the ECM in CNV Growth" subsection), may lead to TIMP-3 accumulation in AMD eyes.<sup>33,187</sup> Leu and coworkers<sup>186</sup> noted that MMP immunoreactivity was present only on the surface of drusen. In situ zymography demonstrated that metal ion-dependent gelatinase activity was absent in drusen cores. Leu and coworkers<sup>186</sup> suggested that the lack of proteolysis in drusen cores might contribute to drusen formation and AMD progression, perhaps in the same way that Sorsby fundus dystrophy mutations, which do not result in loss of TIMP-3 function, foster accumulation of an abnormal ECM.<sup>33,186</sup>

In patients with AMD, delayed choroidal perfusion (as visualized with fluorescein and indocyanine green angiography) and psychophysical retinal functional abnormalities may result from the diffusion barrier created by a thickened, lipid-laden Bruch membrane.<sup>58,188-190</sup>

### Altered RPE-Choriocapillaris Behavior

The accumulation of extracellular debris alters Bruch membrane composition (ie, increased lipid and protein content) and permeability (eg, decreased permeability to water-soluble constituents in plasma, decreased amino acid transport, and possibly decreased bulk flow of extruded RPE-derived cytoplasmic debris across the Bruch membrane).<sup>43,53,59-61</sup> These changes may lead to impaired diffusion of waste products from and of hor-

\*References 34, 56, 127, 136, 138, 140, 175-177.

mones and nutrients to the RPE, including oxygen and vitamin A.<sup>133</sup> In response to this metabolic distress, the RPE probably produces substances that stimulate CNV growth. Several investigators<sup>191-193</sup> have shown that RPE cells associated with CNVs produce VEGF and basic fibroblast growth factor, which may act synergistically to stimulate new blood vessel growth. Macrophages and foreign body giant cells, possibly recruited by activated choroidal dendritic cells, may digest the Bruch membrane and be a source of cytokines that also stimulate CNV growth. Sarks and colleagues<sup>194</sup> noted that activated choroidal capillaries were observed only beneath thinned regions of the Bruch membrane. Sarks observed that Bruch membrane erosion often commences beneath small hard drusen and posited that this phenomenon occurs because angiogenic factors diffuse most readily to the choriocapillaris in these loci rather than through nearby areas containing substantial membranous debris.<sup>194</sup> Choroidal capillaries adjacent to CNVs are often narrowed or absent, which may be a manifestation of RPE dysfunction.<sup>66,89,195,196</sup> This fact may underlie the clinical finding that pulsatile ocular blood flow is lower in eyes with CNVs compared with contralateral eyes with drusen.<sup>197</sup>

**Biochemical Features of CNV Growth.** The RPE may constitutively control angiogenesis beneath the retina.<sup>198</sup> The RPE, for example, produces VEGF *in vivo* under physiologic conditions.<sup>199</sup> VEGF is secreted as a homodimeric protein that is expressed in ischemic retina and stimulates endothelial cell proliferation in blood vessels. The RPE-derived VEGF may maintain the fenestrated choriocapillaris endothelium. Much evidence implicates VEGF in CNV formation. High concentrations of VEGF and VEGF receptors are in CNVs, surrounding tissue, and RPE cells.<sup>191,193,200</sup> Levels of VEGF are increased in cadaver AMD eyes,<sup>200</sup> in the vitreous of patients with AMD,<sup>201</sup> and in the plasma of patients with AMD.<sup>202</sup> Also, VEGF is present in fibroblastic cells and transdifferentiated RPE of surgically removed CNVs.<sup>191</sup> Laser-induced CNVs (in rats and monkeys) are associated with increased VEGF messenger RNA (mRNA) in the RPE, choroidal vascular endothelial cells, and fibroblasts. Intravitreal anti-VEGF antibody fragment (rh-Fab VEGF) prevents laser-induced CNVs in monkeys and decreases leakage from already-formed CNVs.<sup>203</sup> PKC 412, an inhibitor of protein kinase C and the kinases of VEGF and platelet-derived growth factor receptors, prevents laser-induced CNVs in mice.<sup>204</sup>

Increased VEGF expression seems to be sufficient for CNV formation. Schwesinger and coworkers<sup>205</sup> showed that transgenic mice with RPE cells that overexpress VEGF are associated with increased VEGF in the RPE, Bruch membrane, and choroid; increased leukostasis in the choroidal vasculature, probably from up-regulation of intercellular adhesion molecule-1; and intrachoroidal new vessels that do not penetrate the intact Bruch membrane. This result suggests that the presence of increased RPE-derived VEGF must be coupled with some additional factor(s) to develop “typical” sub-RPE and/or subretinal CNVs. The need for RPE–Bruch membrane damage may explain why rats undergoing subretinal injection of adenovirus vector that transfects RPE exhibit CNVs.<sup>206</sup>

Retinal pigment epithelium cells also produce pigment epithelial–derived factor (PEDF), a 50-kDa protein.<sup>207</sup> In addition to neuroprotective effects, PEDF potentially inhibits angiogenesis.<sup>208</sup> Oxidative stress may alter the balance between RPE VEGF and PEDF production.<sup>209</sup> Increased RPE PEDF production inhibits laser-induced CNV growth and induces regression of established CNV in a murine model.<sup>210,211</sup>

Tie-1 and Tie-2 are receptor tyrosine kinases that play a role in the later stages of angiogenesis.<sup>212</sup> Angiopoietins are approximately 75-kDa secreted proteins that target endothelial cell–specific Tie-2 receptors and promote neovascularization in vascular beds, including the retina. Stimulated by angiopoietin-1 (Ang-1), Tie-2 plays a major role in recruiting and sustaining periendothelial support cells (eg, pericytes), resulting in the formation of multicellular vascular structures from simple endothelial tubes.<sup>213,214</sup> Angiopoietin-2 (Ang-2) blocks these functions and, in so doing, may allow vascular remodeling and angiogenesis via stimulatory cytokines, such as VEGF (eg, by reducing endothelial–matrix contact or by dissociating pericytes from endothelial cells).<sup>213</sup> Thus, Ang-1 promotes maturation and stabilization of vessels, and Ang-2 might allow endothelial cells to respond to angiogenic signals.<sup>213,214</sup> Cultured RPE cells express Ang-1 and Ang-2 mRNA, and VEGF up-regulates RPE Ang-1 mRNA and Ang-1 protein secretion.<sup>215</sup> In one study,<sup>216</sup> Ang-1, Ang-2, and Tie-2 immunoreactivity were present in CNVs from AMD eyes. Angiopoietin-1, Ang-2, and VEGF localization were similar, including localization in RPE and vascular cells. Angiopoietin-2 and VEGF immunoreactivity was abundant in highly vascularized regions of the CNVs. Tie-2 immunoreactivity was present in vascular structures and RPE cells. Angiopoietin-1 probably modulates the effect of VEGF on endothelial cells during CNV formation. Retinal pigment epithelium–derived Ang-1 may modulate interactions between endothelial cells and leukocytes during choroidal angiogenesis.

Hypoxia up-regulates Ang-2 mRNA in bovine retinal capillary endothelial cells.<sup>217</sup> Hypoxia also up-regulates VEGF levels (ie, up-regulates VEGF mRNA transcription and increases mRNA stabilization). It is not proved that the documented abnormalities in choroidal blood flow in AMD eyes are sufficient to induce this hypoxia response in the RPE–choroid. Also, it is not proved that the documented thickening, lipidization, and protein cross-linking of the Bruch membrane in AMD alter oxygen diffusion to the RPE photoreceptors. How might oxidative damage and hypoxia play a role in AMD pathogenesis? Perhaps initial oxidative damage leads to excessive formation of an abnormal ECM. Thickened Bruch membrane, combined with factors such as smoking, might then create a relatively hypoxic environment. Relatively minor changes in the diffusion properties of the Bruch membrane or in choroidal blood flow might have seemingly disproportionate effects on the RPE and photoreceptors since the photoreceptors usually consume 90% to 100% of the oxygen delivered by the choriocapillaris.<sup>218</sup> (In the dark-adapted macaque monkey, the oxygen tension near the level of the inner segments is approximately 8 mm Hg vs approximately 50 to 80 mm Hg in the choroid.) Hypoxia could then result in RPE death

and geographic atrophy or in stimulation of CNV growth by hypoxic RPE.

**Role of the ECM in CNV Growth.** Sarkis et al<sup>194</sup> and Campochiaro and coworkers<sup>219</sup> suggested that abnormalities of the RPE ECM may promote a proangiogenic phenotype that fosters CNV growth; CNV growth probably is affected by the nature and quantity of extracellular debris in the sub-RPE space. The risk of CNVs in AMD, for example, increases with increasing number, size, and confluence of drusen. Vitronectin, fibronectin, and advanced glycation end products are molecular constituents of drusen and stimulate production of angiogenic factors in model systems.<sup>220,221</sup> Peroxidized lipids, which accumulate in the Bruch membrane, not only alter Bruch membrane hydraulic conductivity but also stimulate the production of substances that promote neovascularization.<sup>56</sup> Also, ECM molecules can stimulate or inhibit angiogenesis by binding to integrins or by altering integrin expression on endothelial cells (**Table 3**).<sup>204,209,219,222,223</sup>

Matrix metalloproteinases and urokinase plasminogen activator break down the ECM during angiogenesis.<sup>224,225</sup> Matrix metalloproteinase-2 and MMP-9 mRNA, for example, are present in excised CNV specimens,<sup>226</sup> and MMP-2 mRNA is increased in laser-induced CNVs in rats.<sup>227</sup> Degradation of ECM presumably releases and/or activates proangiogenic factors. Proangiogenic factors stimulate proteolytic activity, migration, proliferation, and tube formation in endothelial cells.

**Biological Basis of Geographic Atrophy.** Choriocapillaris density decreases with aging and with AMD. The average choroidal blood flow is lower in patients with dry AMD vs age-matched controls.<sup>228,229</sup> An area dilution analysis technique applied to indocyanine green angiography demonstrated delayed and heterogeneous chorioidal filling in nonneovascular AMD eyes compared with age-matched control eyes.<sup>230</sup> In AMD, the usual pattern of sinusoidal capillary lobules (ie, a central arteriole feeding a sinusoid that drains into peripheral venules) is replaced by a tubular capillary network, which has a lower surface area–volume ratio.<sup>110</sup> This change might be due to primary damage to the choriocapillaris endothelium (eg, oxidative damage mediated by protoporphyrins); might follow the loss of RPE cells (eg, secondary to chronic oxidative damage), with attendant loss of VEGF and other trophic factors<sup>66</sup>; or might arise from a combination of these processes. Photoreceptor death follows RPE cell loss.<sup>132,231</sup>

The biological basis of geographic atrophy in AMD has been reviewed by Sunness.<sup>232</sup> The presence of drusen measuring 250  $\mu\text{m}$  or greater and pigmentary abnormalities are risk factors for the development of geographic atrophy. Increased fundus autofluorescence precedes the development and enlargement of geographic atrophy in AMD.<sup>233</sup> The dominant fluorophores of fundus autofluorescence are part of RPE lipofuscin granules. Thus, excessive RPE lipofuscin accumulation may play a critical role in geographic atrophy pathogenesis in AMD. Histologically, lipofuscin-laden RPE cells are present at the junction of atrophic and normal retina in AMD

**Table 3. Some Stimulators and Inhibitors of Ocular Neovascularization\***

Stimulators
Vascular endothelial growth factor
Fibroblast growth factor
Tumor necrosis factor $\alpha$
Insulin-like growth factor I
Hepatocyte growth factor
Angiopoietin-1 and angiopoietin-2
Hypoxia
Inhibitors
Transforming growth factor $\beta$
Pigment epithelium–derived factor
Peroxisome proliferator–activated receptor $\gamma$ ligands
PKC 412
Angiopoietin-2 (in some systems)

\*Adapted from Seo et al,<sup>204</sup> Ohno-Matsui et al,<sup>209</sup> Campochiaro et al,<sup>219</sup> Asahara et al,<sup>222</sup> and Murata et al.<sup>223</sup>

eyes. The RPE appears increasingly abnormal near the area of atrophy.<sup>44,179</sup> Clinical studies<sup>233</sup> indicate that the area of increased autofluorescence is larger than would be predicted from histologic studies, but no direct clinicopathologic correlation has been made yet. The loss of RPE-derived VEGF might result in the choriocapillaris atrophy seen with atrophic AMD.<sup>89</sup>

Geographic atrophy tends to develop near the fovea, but it tends to spare the foveal center until the later stages of the disease.<sup>231,234,235</sup> One explanation for this observation is as follows.<sup>21,231,236</sup> The highest turnover of outer segments involves rods just outside the fovea, which parallels the distribution of lipofuscin in the RPE. Each RPE cell contacts approximately 45 photoreceptor cells, and each rod outer segment is fully phagocytosed and replaced approximately every 10 days. The RPE continuously discharges cytoplasmic material into the Bruch membrane,<sup>27</sup> which could lead to pathological changes, primarily in the subjacent Bruch membrane. Atrophy of the RPE may be a response to decreased nutrients/increasing metabolic abnormalities in areas of excessive accumulation of extracellular debris. Subfoveal RPE is spared from atrophy the longest, perhaps by macular pigment,<sup>237</sup> the high cone density in the foveola, and possibly other factors. It may be that the subfoveal RPE is the longest-lived source of neovascular signal(s) in this metabolically distressed region, thus accounting for the tendency of CNVs to grow toward the foveola initially and after laser photocoagulation. Choroidal new vessels do not seem to arise from within areas of geographic atrophy but instead tend to arise under adjacent areas in which the RPE-retina seems relatively preserved or under the fovea, if spared.<sup>235</sup>

Among patients with CNVs in one eye and geographic atrophy in the fellow eye, the cumulative incidence of CNVs in the eye with geographic atrophy is 30% to 50% at approximately 5-years' follow-up.<sup>237</sup> Results of histopathologic studies<sup>26,44</sup> indicate that CNVs are present in approximately one third of cases with geographic atrophy. Thus, it seems unlikely that patients with AMD-associated geographic atrophy and AMD-associated CNVs have 2 different diseases.

## Role of Genetics

Findings from genetics studies (reviewed by Yates and Moore<sup>238</sup>) indicate that there is high concordance for AMD among monozygotic twins and relatively lower concordance among dizygotic twins. Age-related macular degeneration is more likely in first-degree relatives than in age-matched controls.<sup>239</sup> One study<sup>240</sup> of monozygotic twins found a genetic effect for the phenotypes of age-related maculopathy (ie, the early stages of AMD), soft drusen, pigmentary changes, and 20 or more hard drusen. The inheritability of age-related maculopathy was estimated to be 45%. During the next few years, molecular biology studies probably will identify mutations in specific genes that alter the risk of developing AMD.<sup>241</sup> At this time, it seems likely that AMD is a polygenic disorder with multiple genes conferring susceptibility to and resistance from the disease. Characterization of the genetic defects underlying the diseases to which we refer currently as AMD may provide an opportunity to identify subtypes of AMD with different disease-causing molecular defects. This approach to nosology may permit better design of clinical trials of therapy, which in turn would enable physicians to provide the proper treatment (especially prophylaxis) at the proper time for any given patient.

Genetic mutations have been identified as the causes of diseases that resemble AMD. Kuntz and coworkers<sup>242</sup> observed that degenerations associated with lipid/mineral deposits in the Bruch membrane are often autosomal dominant and that patients are often asymptomatic until adulthood. Genetic factors probably play a role in the development of geographic atrophy in AMD. Zermatt macular dystrophy, for example, is associated with a dominant mutation of the *RDS/peripherin* gene and is associated with atrophy.<sup>243</sup> A mutation in epidermal growth factor–containing fibrillin-like ECM protein-1 (EFEMP1) causes Malattia Leventinese and Doyme honeycomb retinal dystrophy, which are associated with drusen formation.<sup>244</sup> EFEMP1 is expressed in the RPE and retina and encodes a protein homologous to a family of ECM glycoproteins known as fibulins. *ABCR* gene mutations have been associated with an increased risk of atrophic AMD, but findings from some studies<sup>245,246</sup> indicate that the detected mutations may simply be polymorphisms (ie, mutations that can occur in healthy individuals and do not confer an increased risk) among patients with a common disease. *ABCR*, or rim protein, is a transmembrane protein that may be involved in retinoid transport. As noted in the “Bruch Membrane Thickness” subsection, mutations in *TIMP-3* cause Sorsby fundus dystrophy, which is associated accumulation of abnormal extracellular material in the Bruch membrane, patchy choroidal filling on fluorescein angiography, and CNVs. Despite the similarities between Sorsby fundus dystrophy and AMD, there are differences (eg, younger age of CNV development in the former), and *TIMP-3* mutations do not seem to cause AMD.<sup>247,248</sup> Although lysosomal storage diseases due to single gene defects in metabolism are characterized by accumulations of intracellular material in the RPE, their resemblance to AMD is modest.<sup>249</sup> Cai and coworkers<sup>79</sup> noted that Cock-

ayne syndrome may be a more relevant disease model. In this condition, nucleotide excision repair and transcriptional repair are deficient, which permits cumulative damage to nuclear and mitochondrial genomes throughout life and premature aging.<sup>250</sup> In analogy with mitochondrial myopathies, Cai and coworkers<sup>79</sup> suggested that AMD probably results from progressive damage to the retina and RPE throughout life. Functional capacity (eg, against oxidative damage) in healthy individuals exceeds the threshold below which disease becomes apparent clinically. Genetic background interacts with exposure to environmental risk and protective factors to determine age at disease onset for a given individual. Genetics might affect the susceptibility to develop AMD in the following way.<sup>251</sup> Cellular production of ECM is genetically controlled. Epigenetic factors can alter the ECM, for example, formation of advanced glycation end products. The matrix and matrix degradation products regulate cell phenotype via membrane receptors. The consequences of these interactions can cause disease and/or aging. For example, advanced glycation end products can trigger free radical release and seem to play a role in the accumulation of abnormal extracellular material in Alzheimer disease.<sup>252</sup>

Most AMD cases may not be caused by a single gene defect, even if genes play a major role in determining susceptibility to the disease (eg, by affecting melanin content, antioxidant enzyme activity, and/or MMP activity). Nonetheless, an important benefit of identifying a gene that causes AMD (even if it were to account only for a small fraction of the total patient population) or a condition that very strongly resembles AMD or just a particular aspect of the disease is that one might then construct a biochemical pathway “framework” in which other causes of the disease might be understood and various treatment strategies might be developed.<sup>253</sup> The evidence summarized in this review may provide some insight into the nature of the biochemical pathways involved in AMD pathogenesis and a context in which identified mutations can be studied. The evolution of technologies such as serial analysis of gene expression and microarray analysis may accelerate the identification of genes conferring susceptibility to or protection against AMD and foster the development of complex animal models exhibiting more than 1 gene defect.<sup>254</sup>

## IMPLICATIONS FOR DEVELOPMENT OF THERAPY

Chronic diseases often require a stepwise approach to treatment, and progressive steps usually are associated with increasing degrees of risk to the patient. Generally, the initial approach is prophylaxis, followed by medical therapy, and then surgical therapy. Examples that illustrate this sequence include diabetes mellitus (eg, weight control → oral hypoglycemic agents → insulin therapy → pancreatic islet cell transplantation) and atherosclerosis (eg, diet restriction+exercise → cholesterol-lowering agents → coronary artery stenting and/or bypass surgery). Age-related macular degeneration is a chronic disease; thus, the goal of AMD research should be to develop treatments for the early and later stages of

the disease, as patients will seek care at different stages of the disease and will vary in their response to therapy.

Currently, most treatments for AMD benefit patients with advanced stages of the disease (eg, laser photocoagulation, photodynamic therapy, and surgery for CNVs). Lanchoney and coworkers<sup>255</sup> showed that the addition of a 25% effective bilateral preventive treatment to the conventional laser photocoagulation treatment regimen for CNVs would reduce the rate of legal blindness in the population with bilateral soft drusen relative to current laser treatment by approximately 40% (from 2.24% to 1.34%). Preventive treatment given to the fellow eye after CNVs develop would have substantially less impact (approximately 20% reduction). Thus, treatments for the earlier stages of AMD, even if only modestly effective, can have a great impact on the incidence of AMD-induced blindness.

Better knowledge of AMD pathogenesis will permit the design of effective therapy for earlier stages of the disease. The first proven “early” treatment for AMD is oral therapy with antioxidant vitamins and minerals. Other approaches also may be effective. Dimethyl fumarate, for example, is enriched in apples, increases glutathione, and protects RPE cells from peroxide-induced damage in vitro.<sup>256</sup> Other more potent inducers of glutathione synthesis, such as oltipraz or sulforaphane, have been tested in preclinical trials for cancer prevention.<sup>257</sup> Ahir and coworkers<sup>258</sup> showed that in vitro “transplantation” of cultured RPE cells, which express active MMP-2 and MMP-9, results in improved Bruch membrane hydraulic conductivity. Lipofuscin accumulation in RPE cells can be reduced by treatment with lutein, zeaxanthin, lycopene, or  $\alpha$ -tocopherol<sup>259</sup> or reversed by centrophenoxine treatment.<sup>260</sup> The role of chronic inflammation in AMD pathogenesis has led to the consideration of anti-inflammatory therapy as treatment for the early stages of the disease.<sup>136,138</sup>

Better knowledge of the biological changes underlying AMD will also foster the development of sight-restoring treatments for the late stages of AMD. For example, anti-inflammatory therapy, anti-VEGF therapy, PEDF therapy, anti-Tie-2 therapy (either via ligation of free Ang-1 or via high-level expression of Ang-2, especially in the face of VEGF inhibition), or control of TIMP and MMP expression may permit control of CNV growth without retinal, RPE, or choriocapillary damage.<sup>210,261-266</sup> More precise characterization of AMD-induced Bruch membrane ECM abnormalities probably will permit the design of more effective cellular transplantation surgery, which might serve as a treatment for exudative and atrophic AMD.<sup>267-269</sup> Neurotrophic agents, which promote neuron survival, might be useful for preserving vision in patients with atrophic and exudative manifestations of AMD.<sup>270</sup> Gene therapy with PEDF might be an example of combined therapy, in which the treatment inhibits CNV growth and promotes photoreceptor survival via a neurotrophic effect (see the “Biochemical Features of CNV Growth” subsection).

## CONCLUSIONS

Five general concepts relevant to the cell biology of AMD have been described (Figure 2). First, AMD involves aging changes plus additional pathological events. Sec-

ond, in aging and AMD, oxidative stress causes RPE and, possibly, choriocapillaris injury. Third, in AMD (and perhaps in aging), RPE and, possibly, choriocapillaris injury results in a chronic inflammatory response in the Bruch membrane and the choroid. Fourth, in AMD, RPE and, possibly, choriocapillaris injury and inflammation lead to formation of an abnormal ECM. This abnormal ECM causes altered diffusion of nutrients to the retina and RPE, which may precipitate further RPE and retinal damage. Fifth, the abnormal ECM results in altered RPE-choriocapillaris behavior, leading ultimately to atrophy of the retina, RPE, and choriocapillaris and/or to CNV growth. In this pathogenetic sequence of events, environment and genetics can alter any given patient’s susceptibility to the disease. Manipulation of environmental variables (eg, antioxidant levels) provides an opportunity for early therapeutic intervention. Gene and/or cellular therapy provide an opportunity for later, sight-restoring treatment. Implicit in this characterization of AMD pathogenesis is the concept that there is linear progression from one stage of the disease to the next. This assumption may be incorrect, and different biochemical pathways leading to geographic atrophy and/or CNVs may operate simultaneously. Additional experimentation with in vitro and in vivo models will prove or refute the concept of linear progression and will establish the identities of the various pathways that lead to CNVs and geographic atrophy.

Better knowledge of AMD cell biology will lead to better treatments for AMD at all stages of the disease, as results from the Age-Related Eye Disease Study<sup>90</sup> and the Verteporfin in Photodynamic Therapy study<sup>4</sup> imply. Many unanswered questions regarding AMD pathogenesis remain. For example, if Bruch membrane permeability change plays in the evolution of AMD, is it reversible? If oxidative damage precipitates the development of geographic atrophy and CNV growth, what additional factors determine the development of atrophy vs CNV in any given patient or location within a given eye? For any given patient, can a risk profile and a “prophylactic treatment” plan be established based on genotype analysis? The development of transgenic animal models of AMD and better in vivo RPE–Bruch membrane imaging modalities will accelerate progress in answering these questions. It seems that multiple genes confer susceptibility to and resistance from AMD. Thus, animal models exhibiting multiple genetic changes may be needed to consistently reproduce all aspects of AMD. New techniques, such as serial analysis of gene expression, may be critical for the identification of these genes. Until such complex animal models are developed, there probably will be an ongoing need for simpler animal models and for in vitro models of specific aspects of AMD so that the development of effective therapies for different stages of AMD can continue.

*Submitted for publication February 6, 2002; final revision received July 15, 2003; accepted August 4, 2003.*

*This study was supported in part by Research to Prevent Blindness Inc, New York, NY, the New Jersey Lions Eye Research Foundation, Newark, and the Eye Institute of New Jersey, Newark.*

Corresponding author and reprints: Marco A. Zarbin, MD, PhD, The Institute of Ophthalmology and Visual Science, New Jersey Medical School, 90 Bergen St, Suite 6100, Newark, NJ 07103-2499 (e-mail: zarbin@njmsa.umdnj.edu).

## REFERENCES

- Klein R, Klein BE, Jensen SC, Meuer SM. The five-year incidence and progression of age-related maculopathy: the Beaver Dam Eye Study. *Ophthalmology*. 1997;104:7-21.
- Gass JDM. *Stereoscopic Atlas of Macular Diseases: Diagnosis and Management*. 4th ed. St Louis, Mo: Mosby-Year Book Inc, 1997:70-105.
- Guyor DR, Fine SL, Maguire MG, Hawkins BS, Owens SL, Murphy RP. Subfoveal choroidal neovascular membranes in age-related macular degeneration: visual prognosis in eyes with relatively good initial visual acuity. *Arch Ophthalmol*. 1986;104:702-705.
- Bressler NM. Verteporfin therapy of subfoveal choroidal neovascularization in age-related macular degeneration: two year results of a randomized clinical trial including lesions with occult with no classic choroidal neovascularization: Verteporfin in Photodynamic Therapy report 2. *Am J Ophthalmol*. 2002;133:168-169.
- Klein R, Klein BE, Linton KL. Prevalence of age-related maculopathy: the Beaver Dam Eye Study. *Ophthalmology*. 1992;99:933-943.
- Klein R, Klein BE, Franke T. The relationship of cardiovascular disease and its risk factors to age-related maculopathy: the Beaver Dam Eye Study. *Ophthalmology*. 1993;100:406-414.
- Vingerling JR, Dielemans I, Hofman A, et al. The prevalence of age-related maculopathy in the Rotterdam Study. *Ophthalmology*. 1995;102:205-210.
- Evans J, Wormald R. Is the incidence of registrable age-related macular degeneration increasing? *Br J Ophthalmol*. 1996;80:9-14.
- Harman D. Ageing: a theory based on free radical and radiation chemistry. *J Gerontol*. 1956;11:298-300.
- Wallace DC. Mitochondrial diseases in man and mouse. *Science*. 1999;283:1482-1488.
- Verzar F. Aging of connective tissue. *Gerontologia*. 1957;1:363-378.
- Robert L. Mechanisms of aging of the extracellular matrix: role of the elastin-laminin receptor. *Gerontology*. 1998;44:307-317.
- Chandrasekhar S, Sorrentino JA, Millis AJ. Interaction of fibronectin with collagen: age-specific defect in the biological activity of human fibroblast fibronectin. *Proc Natl Acad Sci U S A*. 1983;80:4747-4751.
- Murano S, Thweatt R, Shmookler-Reis RJ, Jones RA, Moerman EJ, Goldstein S. Diverse gene sequences are overexpressed in Werner syndrome fibroblasts undergoing premature replicative senescence. *Mol Cell Biol*. 1991;11:3905-3914.
- Hu Q, Moerman EJ, Goldstein S. Altered expression and regulation of the  $\alpha 5\beta 1$  integrin-fibronectin receptor lead to reduced amounts of functional  $\alpha 5\beta 1$  heterodimer on the plasma membrane of senescent human diploid fibroblasts. *Exp Cell Res*. 1996;224:251-263.
- Rasoamanantana P, Thweatt R, Labat-Robert J, Goldstein S. Altered regulation of fibronectin gene expression in Werner syndrome fibroblasts. *Exp Cell Res*. 1994;213:121-127.
- Yu CE, Oshima J, Wijsman EM, et al. Mutations in the consensus helicase domains of the Werner syndrome gene: Werner's Syndrome Collaborative Group. *Am J Hum Genet*. 1997;60:330-341.
- Maillard LC. Action des acides amines sur les sucres: formation des melanoidines par voie methodique. *C R Hebd Seances Acad Sci*. 1912;154:66-68.
- Feeney-Burns L, Hilderbrand ES, Eldridge S. Aging human RPE: morphometric analysis of macular, equatorial, and peripheral cells. *Invest Ophthalmol Vis Sci*. 1984;25:195-200.
- Sundelin SP, Wihlmark U, Nilsson SEG, Brunk UT. Lipofuscin accumulation in cultured retinal pigment epithelial cells reduces their phagocytic capacity. *Curr Eye Res*. 1998;17:851-857.
- Kennedy CJ, Rakoczy PE, Constable IJ. Lipofuscin of the retinal pigment epithelium: a review. *Eye*. 1995;9(pt 6):763-771.
- Okubo A, Rosa RH Jr, Bunce CV, et al. The relationship of age changes in retinal pigment epithelium and Bruch's membrane. *Invest Ophthalmol Vis Sci*. 1999;40:443-449.
- Ramrattan RS, van der Schaft TL, Mooy CM, de Bruijn WC, Mulder PGH, de Jong PTVM. Morphometric analysis of Bruch's membrane, the choriocapillaris and the choroid in ageing. *Invest Ophthalmol Vis Sci*. 1994;35:2857-2864.
- Newsome DA, Huh W, Green WR. Bruch's membrane age-related changes vary by region. *Curr Eye Res*. 1987;6:1211-1221.
- Farkas TG, Sylvester V, Archer D, Altona M. The histochemistry of drusen. *Am J Ophthalmol*. 1971;71:1206-1215.
- Sarks SH. Aging and degeneration in the macular region: a clinicopathologic study. *Br J Ophthalmol*. 1976;60:324-341.
- Burns RP, Feeney-Burns L. Clinicomorphologic correlations of drusen and Bruch's membrane. *Trans Am Ophthalmol Soc*. 1980;78:206-223.
- Ruiz A, Brett P, Bok D. TIMP-3 is expressed in the human retinal pigment epithelium. *Biochem Biophys Res Commun*. 1996;226:467-474.
- Alexander JP, Bradley JMB, Gabourel JC, Acott TS. Expression of matrix metalloproteinases and inhibitors by human retinal pigment epithelium. *Invest Ophthalmol Vis Sci*. 1990;31:2520-2528.
- Leu ST, Batni S, Radeke MJ, Johnson LV, Anderson DH, Clegg DO. Drusen are cold spots for proteolysis: expression of matrix metalloproteinases and their tissue inhibitor proteins in age-related macular degeneration. *Exp Eye Res*. 2002;74:141-154.
- Guo L, Hussain AA, Limb GA, Marshall J. Age-dependent variation in metalloproteinase activity of isolated human Bruch's membrane and choroid. *Invest Ophthalmol Vis Sci*. 1999;40:2676-2682.
- Weber BH, Vogt G, Pruett RC, Stohr H, Felbor U. Mutations in the tissue inhibitor of metalloproteinases-3 (TIMP-3) in patients with Sorsby's fundus dystrophy. *Nat Genet*. 1994;8:352-356.
- Langton KP, Barker MD, McKie N. Localization of the functional domains of human tissue inhibitor of metalloproteinases-3 and the effects of a Sorsby's fundus dystrophy mutation. *J Biol Chem*. 1998;273:16778-16781.
- Kamei M, Hollyfield JG. TIMP-3 in Bruch's membrane: changes during aging and in age-related macular degeneration. *Invest Ophthalmol Vis Sci*. 1999;40:2367-2375.
- Bailey TA, Alexander RA, Dubovy SR, Luthert PJ, Chong NHV. Measurement of TIMP-3 expression and Bruch's membrane thickness in human macula. *Exp Eye Res*. 2001;73:851-858.
- Jacobson SG, Cideciyan AV, Regunath G, et al. Night blindness in Sorsby's fundus dystrophy reversed by vitamin A. *Nat Genet*. 1995;11:27-32.
- Das A, Frank RN, Zhang NL, Turezyn TJ. Ultrastructural localization of extracellular matrix components in human retinal vessels and Bruch's membrane. *Arch Ophthalmol*. 1990;108:421-429.
- Hewitt AT, Nakazawa K, Newsome DA. Analysis of newly synthesized Bruch's membrane proteoglycans. *Invest Ophthalmol Vis Sci*. 1989;30:478-486.
- Marshall J, Hussain AA, Starita C, Moore DJ, Patmore AL. Aging and Bruch's membrane. In: Marmor MF, Wolfensberger TJ, eds. *The Retinal Pigment Epithelium*. New York, NY: Oxford University Press; 1998:669-692.
- Hogan MJ, Alvarado J. Studies on the human macula, IV: aging changes in Bruch's membrane. *Arch Ophthalmol*. 1967;77:410-420.
- Starita C, Hussain AA, Pagliarini S, Marshall J. Hydrodynamics of ageing Bruch's membrane: implications for macular disease. *Exp Eye Res*. 1996;62:565-572.
- Starita C, Hussain AA, Patmore A, Marshall J. Localization of the site of major resistance to fluid transport in Bruch's membrane. *Invest Ophthalmol Vis Sci*. 1997;38:762-767.
- Karwatowski WS, Jeffries TE, Duance VC, Albon J, Bailey AJ, Easty DL. Preparation of Bruch's membrane and analysis of the age-related changes in the structural collagens. *Br J Ophthalmol*. 1995;79:944-952.
- Green WR, Enger C. Age-related macular degeneration histopathologic studies: the 1992 Lorenz E Zimmerman Lecture. *Ophthalmology*. 1993;100:1519-1535.
- Loeffler KU, Lee WR. Is basal laminar deposit unique for age-related macular degeneration? *Arch Ophthalmol*. 1992;110:15-16.
- Loeffler KU, Lee WR. Basal linear deposit in the human macula. *Graefes Arch Clin Exp Ophthalmol*. 1986;24:493-501.
- Pauleikhoff P, Wojtecki S, Muller D, Boulton S, Boulton M, Heiligenhaus A. Adhesion molecules and lipid accumulation in Bruch's membrane with age. *Invest Ophthalmol Vis Sci*. 1999;40:S920.
- Curcio CA, Millican CL. Basal linear deposit and large drusen are specific for early age-related maculopathy. *Arch Ophthalmol*. 1999;117:329-339.
- Handa JT, Verzijl N, Matsunaga H, et al. Increase in the advanced glycation end product pentosidine in Bruch's membrane with age. *Invest Ophthalmol Vis Sci*. 1999;40:775-779.
- Schmidt AM, Yan SD, Yan SF, Stern DM. The biology of the receptor for advanced glycation end products and its ligands. *Biochim Biophys Acta*. 2000;1498:99-111.
- King G, Brownlee M. The cellular and molecular mechanisms of diabetic complications. *Endocrinol Metab Clin North Am*. 1996;25:255-270.
- Lyda W, Eriksen N, Krishna N. Studies of Bruch's membrane: flow and permeability studies in a Bruch's membrane-choroid preparation. *Am J Ophthalmol*. 1957;44:362-370.
- Moore DJ, Hussain AA, Marshall J. Age-related variation in the hydraulic conductivity of Bruch's membrane. *Invest Ophthalmol Vis Sci*. 1995;36:1290-1297.
- Holz FG, Sheridah G, Pauleikhoff D, Bird AC. Analysis of lipid deposits ex-

- tracted from human macular and peripheral Bruch's membrane. *Arch Ophthalmol*. 1994;112:402-406.
55. Sheraidah G, Steinmetz R, Maguire J, Pauleikhoff D, Marshall J, Bird AC. Correlation between lipids extracted from Bruch's membrane and age. *Ophthalmology*. 1993;100:47-51.
  56. Spaide RF, Ho-Spaide WC, Browne RW, Armstrong D. Characterization of peroxidized lipids in Bruch's membrane. *Retina*. 1999;19:141-147.
  57. Hogan MJ, Alvarado JA, Weddell JE. *Histology of the Human Eye: An Atlas and Textbook*. Philadelphia, Pa: WB Saunders Co; 1971.
  58. Pauleikhoff D, Chen JC, Chisholm IH, Bird AC. Choroidal perfusion abnormality with age-related Bruch's membrane change. *Am J Ophthalmol*. 1990;109:211-217.
  59. Moore DJ, Clover GM. The effect of age on the macromolecular permeability of human Bruch's membrane. *Invest Ophthalmol Vis Sci*. 2001;42:2970-2975.
  60. Hussain AA, Rowe L, Marshall J. Age-related alterations in the diffusional transport of amino acids across the human Bruch's-choroid complex. *J Opt Soc Am A Opt Image Sci Vis*. 2002;19:166-172.
  61. Pauleikhoff D, Sheraidah G, Marshall J, Bird AC, Wessing A. Biochemical and histochemical analysis of age related lipid deposits in Bruch's membrane. *Ophthalmology*. 1994;91:730-734.
  62. Luty G, Grunwald J, Majji AB, Uyama M, Yoneya S. Changes in choriocapillaris and retinal pigment epithelium (RPE) in age-related macular degeneration. *Mol Vis*. 1999;5:35-38.
  63. Pauleikhoff D, Harper CA, Marshall J, Bird AC. Aging changes in Bruch's membrane: a histochemical and morphologic study. *Ophthalmology*. 1990;97:171-178.
  64. Grunwald J, Hariprasad S, Dupont J. Effect of aging on foveolar choroidal circulation. *Arch Ophthalmol*. 1998;116:150-154.
  65. Guymer R, Luthert P, Bird A. Changes in Bruch's membrane and related structures with age. *Prog Retin Eye Res*. 1999;18:59-90.
  66. Korte GE, Burns MS, Bellhorn RW. Epithelium-capillary interactions in the eye: the retinal pigment epithelium and the choriocapillaris. *Int Rev Cytol*. 1989;114:221-248.
  67. Wallace DC, Brown MD, Melov S, Graham B, Lott M. Mitochondrial biology, degenerative diseases and aging. *Biofactors*. 1998;7:187-190.
  68. Samiec PS, Drews-Botsch C, Flagg EW, et al. Glutathione in human plasma: decline in association with aging, age-related macular degeneration, and diabetes. *Free Radic Biol Med*. 1998;24:699-704.
  69. Rikans LE, Moore DR. Effect of aging on aqueous-phase antioxidants in tissues of male Fischer rats. *Biochim Biophys Acta*. 1988;966:269-275.
  70. Vandewoude MFJ, Vandewoude MG. Vitamin E status in normal population: the influence of age. *J Am Coll Nutr*. 1987;6:307-311.
  71. Coudray C, Roussel AM, Arnaud J, Favier A. Selenium and antioxidant vitamin and lipid peroxidation levels in preaging French population: EVA Study Group. *Biol Trace Elem Res*. 1997;57:183-190.
  72. Castorina C, Campisi A, Di Giacomo C, Sorrenti V, Russo A, Vanella A. Lipid peroxidation and antioxidant enzymatic systems in rat retina as a function of age. *Neurochem Res*. 1992;17:599-604.
  73. Liles MR, Newsome DA, Oliver PD. Antioxidant enzymes in the aging human retinal pigment epithelium. *Arch Ophthalmol*. 1991;109:1285-1288.
  74. Friedrichson T, Kalbach H, Buck P, van Kuijk F. Vitamin E in macular and peripheral tissues of the human eye. *Curr Eye Res*. 1995;14:693-701.
  75. Beatty S, Koh H-H, Henson D, Boulton M. The role of oxidative stress in the pathogenesis of age-related macular degeneration. *Surv Ophthalmol*. 2000;45:115-134.
  76. Davies S, Mulroy L, McGarvey D, Truscott TG, Boulton M. The phototoxicity of lipofuscin. *Invest Ophthalmol Vis Sci*. 1998;39:S129.
  77. Panda-Jonas S, Jonas J, Jakobczyk-Kmija M. Retinal pigment epithelial cell count distribution, and correlations in normal eyes. *Am J Ophthalmol*. 1996;121:181-189.
  78. Winkler BS, Boulton ME, Gottsch JD, Sternberg P. Oxidative damage and age-related macular degeneration. *Mol Vis*. 1999;5:32-46.
  79. Cai J, Nelson KC, Wu M, Sternberg P, Jones DP. Oxidative damage and protection of the RPE. *Prog Retin Eye Res*. 2000;19:205-221.
  80. De La Paz M, Anderson RE. Region and age-dependent variation in susceptibility of the human retina to lipid peroxidation. *Invest Ophthalmol Vis Sci*. 1992;33:3497-3499.
  81. Boulton M, Donstov A, Jarvis-Evans J, Ostrovsky M, Svistunenko D. Lipofuscin is a photoinducible free radical generator. *J Photochem Photobiol B*. 1993;19:201-204.
  82. Holz FG, Schutt F, Kopitz J, et al. Inhibition of lysosomal degradative functions in RPE cells by a retinoid component of lipofuscin. *Invest Ophthalmol Vis Sci*. 1999;40:737-743.
  83. Wassell J, Davies S, Bardsley W, Boulton M. The photoreactivity of the retinal age pigment lipofuscin. *J Biol Chem*. 1999;274:23828-23832.
  84. Katz ML, Christianson JS, Gao CL, Handlemen GL. Iron-induced fluorescence in the retina: dependence on vitamin A. *Invest Ophthalmol Vis Sci*. 1994;35:3613-3624.
  85. Sakai N, Decatur J, Nakanishi K, Eldred G. Ocular age pigment "A2E": an unprecedented pyridinium bisretinoid. *J Am Chem Soc*. 1996;118:1559-1560.
  86. Schutt F, Davies S, Kopitz J, Holz FG, Boulton ME. Photodamage to human RPE cells by A2-E, a retinoid component of lipofuscin. *Invest Ophthalmol Vis Sci*. 2000;41:2303-2308.
  87. Finnemann SC, Leung LW, Rodriguez-Boulan E. The lipofuscin component A2E selectively inhibits phagolysosomal degradation of photoreceptor phospholipid by the retinal pigment epithelium. *Proc Natl Acad Sci U S A*. 2002;99:3842-3847.
  88. Crabb JW, Miyagi M, Gu X, et al. Drusen proteome analysis: an approach to the etiology of age-related macular degeneration. *Proc Natl Acad Sci U S A*. 2002;99:14682-14687.
  89. McLeod DS, Taomoto M, Otsuji T, Green WR, Sunness JS, Luty GA. Quantifying changes in RPE and choroidal vasculature in eyes with age-related macular degeneration. *Invest Ophthalmol Vis Sci*. 2002;43:1986-1993.
  90. Age-Related Eye Disease Study Group. A randomized, placebo-controlled clinical trial of high-dose supplementation with vitamins C and E, beta carotene, and zinc for age-related macular degeneration and visual loss. *Arch Ophthalmol*. 2001;119:1417-1436.
  91. Karcioğlu ZA. Zinc in the eye. *Surv Ophthalmol*. 1982;27:114-122.
  92. Eye Disease Case Control Study Group. Antioxidant status and neovascular age-related macular degeneration. *Arch Ophthalmol*. 1993;111:104-109.
  93. West S, Vitale S, Hallfrisch J, et al. Are antioxidants or supplements protective for age-related macular degeneration? *Arch Ophthalmol*. 1994;112:222-227.
  94. VandenLangenberg GM, Mares-Perlman JA, Klein R, Klein BE, Brady WE, Palta M. Associations between antioxidant and zinc intake and the 5-year incidence of early age-related maculopathy in the Beaver Dam Eye Study. *Am J Epidemiol*. 1998;148:204-214.
  95. Delcourt C, Cristol JP, Tessier F, Leger CL, Descomps B, Papoz L. Age-related macular degeneration and antioxidant status in the POLA study: POLA Study Group: Pathologies Oculaires Liees à l'Age. *Arch Ophthalmol*. 1999;117:1384-1390.
  96. Seddon JM, Ajani UA, Sperduto RD, et al. Dietary carotenoids, vitamins A, C, and E, and advanced age-related macular degeneration: Eye Disease Case-Control Study Group. *JAMA*. 1994;272:1413-1420.
  97. Smith W, Mitchell P, Webb K, Leeder SR. Dietary antioxidants and age-related maculopathy: the Blue Mountains Eye Study. *Ophthalmology*. 1999;106:761-767.
  98. Hawkins BS, Bird A, Klein R, West SK. Epidemiology of age-related macular degeneration. *Mol Vis*. 1999;5:26-29.
  99. Friedman DS, Katz J, Bressler NM, Rahmani B, Tielsch JM. Racial differences in the prevalence of age-related macular degeneration. *Ophthalmology*. 1999;106:1049-1055.
  100. Age-Related Eye Disease Study Research Group. Risk factors associated with age-related macular degeneration: a case-control study in the age-related eye disease study: age-related eye disease study report number 3. *Ophthalmology*. 2000;107:2224-2232.
  101. Vingerling JR, Klaver CC, Hofman A, de Jong PT. Epidemiology of age-related maculopathy. *Epidemiol Rev*. 1995;17:347-360.
  102. Wallace DC. Mitochondrial DNA in aging and disease. *Sci Am*. 1997;277:40-47.
  103. Chow CK, Thacker RR, Changchit C, et al. Lower levels of vitamin C and carotenoids in plasma of cigarette smokers. *J Am Coll Nutr*. 1986;5:305-312.
  104. Church DF, Pryor WA. Free-radical chemistry of cigarette smoke and its toxicological implications. *Environ Health Perspect*. 1985;64:111-126.
  105. Friedman DS, Katz J, Bressler NM, Rahmani B, Tielsch JM. Racial differences in the prevalence of age-related macular degeneration: the Baltimore Eye Survey. *Ophthalmology*. 1999;106:1049-1055.
  106. Klein R, Klein BE, Cruickshanks KJ. The prevalence of age-related maculopathy by geographic region and ethnicity. *Prog Retin Eye Res*. 1999;18:371-389.
  107. Sundelin SP, Nilsson SEG, Brunk UT. Lipofuscin-formation in cultured retinal pigment epithelial cells is related to their melanin content. *Free Radic Biol Med*. 2001;30:74-81.
  108. Weiter JJ, Delori FC, Wing GL, Fitch KA. Retinal pigment epithelial lipofuscin and melanin and choroidal melanin in human eyes. *Invest Ophthalmol Vis Sci*. 1986;27:145-152.
  109. Gottsch JD, Pou S, Bynoe LA, Rosen GM. Hematogenous photosensitization: a mechanism for the development of age-related macular degeneration. *Invest Ophthalmol Vis Sci*. 1990;31:1674-1682.
  110. Torczynski E, Tso MOM. The architecture of the choriocapillaris at the posterior pole. *Am J Ophthalmol*. 1976;81:428-440.
  111. Cai J, Wu M, Nelson K, Jones DP, Sternberg P Jr. Oxidant induced apoptosis in

- cultured human retinal pigment epithelial cells. *Invest Ophthalmol Vis Sci*. 1999; 40:959-966.
112. Frank RN, Amin RH, Puklin JE. Antioxidant enzymes in the macular retinal pigment epithelium of eyes with neovascular age-related macular degeneration. *Am J Ophthalmol*. 1999;127:694-709.
  113. Tate DJ Jr, Newsome DA, Oliver PD. Metallothionein shows an age-related decrease in human macular retinal pigment epithelium. *Invest Ophthalmol Vis Sci*. 1993;34:2348-2351.
  114. Cohen SM, Olin KL, Feuer WJ, Hjelmeland L, Keen CL, Morse LS. Low glutathione reductase and peroxidase activity in age-related macular degeneration. *Br J Ophthalmol*. 1994;78:791-794.
  115. Delcourt C, Cristol JP, Leger CL, Descamps B, Papoz L. Associations of antioxidant enzymes with cataract and age-related macular degeneration: The POLA Study: Pathologies Oculaires Liées à l'Age. *Ophthalmology*. 1999;106: 215-222.
  116. Packer L. Antioxidant action of carotenoids in vitro and in vivo and protection against oxidation of human low-density lipoproteins. *Ann N Y Acad Sci*. 1993; 691:48-60.
  117. Bohm F, Tinkler JH, Truscott TG. Carotenoids protect against cell membrane damage by the nitrogen dioxide radical. *Nat Med*. 1995;1:98-99.
  118. Hammond BR Jr, Curran-Celentano J, Judd S, et al. Sex differences in macular pigment optical density: relation to plasma carotenoid concentrations and dietary patterns. *Vision Res*. 1996;36:2001-2012.
  119. Hammond BR, Wooten BR, Snodderly DM. Cigarette smoking and retinal carotenoids: implications for age-related macular degeneration. *Vision Res*. 1996; 36:3003-3009.
  120. Hammond BR Jr, Fuld K, Snodderly DM. Iris color and macular pigment optical density. *Exp Eye Res*. 1996;62:293-297.
  121. Hammond BR Jr, Wooten BR, Snodderly DM. Density of the human crystalline lens is related to the macular pigment carotenoids, lutein and zeaxanthin. *Optom Vis Sci*. 1997;74:499-504.
  122. Berendschot TTJM, Willems-Assink JJM, Bastiaanse M, de Jong PTVM, van Norren D. Macular pigment and melanin in age-related maculopathy in a general population. *Invest Ophthalmol Vis Sci*. 2002;43:1928-1932.
  123. Landrum JT, Bone RA, Kilburn MD. The macular pigment: a possible role in protection from age-related macular degeneration. *Adv Pharmacol*. 1997;38: 537-556.
  124. Bone RA, Landrum JT, Mayne ST, Gomez CM, Tibor SE, Twaroska EE. Macular pigment in donor eyes with and without AMD: a case-control study. *Invest Ophthalmol Vis Sci*. 2001;42:235-240.
  125. Beatty S, Murray IJ, Henson DB, Carden D, Koh H-H, Boulton ME. Macular pigment and risk for age-related macular degeneration in subjects from a northern European population. *Invest Ophthalmol Vis Sci*. 2001;42:439-446.
  126. Hernandez E, Sall J, Alexandridou A, Dix R, Csaky KG, Cousins SW. Polyunsaturated fat increases RPE susceptibility to lipid peroxidation: a mechanism for BLD formation? *Invest Ophthalmol Vis Sci*. 1999;40:S927.
  127. Ishibashi T, Murata T, Hangai M, et al. Advanced glycation end products in age-related macular degeneration. *Arch Ophthalmol*. 1998;116:1629-1632.
  128. Honda S, Farboud B, Hjelmeland LM, Handa JT. Induction of an aging mRNA retinal pigment epithelial cell phenotype by matrix-containing advanced glycation end products in vitro. *Invest Ophthalmol Vis Sci*. 2001;42:2419-2425.
  129. Hammes HP, Hoerauf H, Alt A, et al. N(epsilon)-(carboxymethyl)lysine and the AGE receptor RAGE co-localize in age-related macular degeneration. *Invest Ophthalmol Vis Sci*. 1999;40:1855-1859.
  130. Delori FC, Fleckner MR, Goger DG, Weiter JJ, Dorey CK. Autofluorescence distribution associated with drusen in age-related macular degeneration. *Invest Ophthalmol Vis Sci*. 2000;41:496-504.
  131. Lois M, Owens SL, Coco R, Hopkins J, Fitzke FW, Bird AC. Fundus autofluorescence in patients with age-related macular degeneration and high risk of visual loss. *Am J Ophthalmol*. 2002;133:341-349.
  132. Green WR, Key S. Senile macular degeneration: a histopathologic study. *Trans Am Ophthalmol Soc*. 1977;75:180-254.
  133. Grindle CFJ, Marshall J. Ageing changes in Bruch's membrane and their functional implications. *Trans Ophthalmol Soc U K*. 1978;98:172-175.
  134. Penfold P, Killingsworth M, Sarks S. An ultrastructural study of the role of leucocytes and fibroblasts in the breakdown of Bruch's membrane. *Aust J Ophthalmol*. 1984;12:23-31.
  135. Penfold PL, Provis JM, Billson FA. Age-related macular degeneration: ultrastructural studies of the relationship of leucocytes to angiogenesis. *Graefes Arch Clin Exp Ophthalmol*. 1987;225:70-76.
  136. Hageman GS, Luthert PJ, Chong VNH, Johnson LV, Anderson DH, Mullins RF. An integrated hypothesis that considers drusen as biomarkers of immune-mediated processes at the RPE-Bruch's membrane interface in aging and age-related macular degeneration. *Prog Retin Eye Res*. 2001;20:705-732.
  137. Johnson LV, Leitner WP, Staples MK, Anderson DH. Complement activation and inflammatory processes in drusen formation and age-related macular degeneration. *Exp Eye Res*. 2001;73:887-896.
  138. Anderson DH, Mullins RF, Hageman GS, Johnson LV. A role for local inflammation in the formation of drusen in the aging eye. *Am J Ophthalmol*. 2002; 134:411-431.
  139. Hageman G, Mullins R, Russell S, Johnson L, Anderson D. Vitronectin is a constituent of ocular drusen and the vitronectin gene is expressed in human retinal pigmented epithelial cells. *FASEB J*. 1999;13:477-484.
  140. Johnson L, Ozaki S, Staples M, Erickson P, Anderson D. A potential role for immune complex pathogenesis in drusen formation. *Exp Eye Res*. 2000;70: 441-449.
  141. Mullins R, Anderson D, Russell S, Hageman G. Ocular drusen contain proteins common to extracellular deposits associated with atherosclerosis, elastosis, amyloidosis, and dense deposit disease. *FASEB J*. 2000;14:835-846.
  142. Sakaguchi H, Miyagi M, Shadrach KG, Rayborn ME, Crabb JW, Hollyfield JG. Clusterin is present in drusen in age-related macular degeneration. *Exp Eye Res*. 2002;74:547-549.
  143. Ishibashi T, Patterson R, Ohnishi Y, Inomata H, Ryan SJ. Formation of drusen in the human eye. *Am J Ophthalmol*. 1986;101:342-353.
  144. Feeney-Burns L, Eilersieck MR. Age-related changes in the ultrastructure of Bruch's membrane. *Am J Ophthalmol*. 1985;100:686-697.
  145. Killingsworth MC. Age-related components of Bruch's membrane in the human eye. *Graefes Arch Clin Exp Ophthalmol*. 1987;225:406-412.
  146. Mullins R, Aptsiauri N, Hageman G. Dendritic cells and proteins associated with immune-mediated processes are associated with drusen and may play a central role in drusen biogenesis. *Invest Ophthalmol Vis Sci*. 2000;41:S24.
  147. Anderson DH, Ozaki S, Nealon M, et al. Local cellular sources of apolipoprotein E in the human retina and retinal pigmented epithelium: implications for the process of drusen formation. *Am J Ophthalmol*. 2001;131:767-781.
  148. Penfold PL, Liew SC, Madigan MC, Provis JM. Modulation of major histocompatibility complex class II expression in retinas with age-related macular degeneration. *Invest Ophthalmol Vis Sci*. 1997;38:2125-2133.
  149. Dastgheib K, Green W. Granulomatous reaction to Bruch's membrane in age-related macular degeneration. *Arch Ophthalmol*. 1994;112:813-818.
  150. Penfold P, Killingsworth M, Sarks S. Senile macular degeneration: the involvement of immunocompetent cells. *Graefes Arch Clin Exp Ophthalmol*. 1985;223: 69-76.
  151. Killingsworth M, Sarks J, Sarks S. Macrophages related to Bruch's membrane in age-related macular degeneration. *Eye*. 1990;4:613-621.
  152. Seregard S, Algvere PV, Berglin L. Immunohistochemical characterization of surgically removed subfoveal fibrovascular membranes. *Graefes Arch Clin Exp Ophthalmol*. 1994;32:325-329.
  153. Hutchinson AK, Grossniklaus HE, Capone A. Giant-cell reaction in surgically excised subretinal neovascular membrane. *Arch Ophthalmol*. 1993;111:734-735.
  154. Otani A, Takagi H, Oh H, Koyama S, Matsumura M, Honda Y. Expressions of angiopoietins and Tie2 in human choroidal neovascular membranes. *Invest Ophthalmol Vis Sci*. 1999;40:1912-1920.
  155. Oh H, Takagi H, Takagi C, et al. The potential angiogenic role of macrophages in the formation of choroidal neovascular membranes. *Invest Ophthalmol Vis Sci*. 1999;40:1891-1898.
  156. Heriot WJ, Henkind P, Belhorn RW, Burns MS. Choroidal neovascularization can digest Bruch's membrane: a prior break is not essential. *Ophthalmology*. 1984;91:1603-1608.
  157. Fulp T Jr, Jacob MP, Varga Z, Foris G, Leovey A, Robert L. Effect of elastin peptides on human monocytes: Ca<sup>2+</sup> mobilization, stimulation of respiratory burst and enzyme secretion. *Biochem Biophys Res Commun*. 1986;141:92-98.
  158. Faury G, Ristori MT, Verdetti J, Jacob MP, Robert L. Effect of elastin peptides on vascular tone. *J Vasc Res*. 1995;32:112-119.
  159. Van der Schaft T, Mooy CM, de Bruijn WC, de Jong PT. Early stages of age-related macular degeneration: an immunofluorescence and electron microscopy study. *Br J Ophthalmol*. 1993;77:657-661.
  160. Streilein JW, Ma N, Wenkel H, Ng TF, Zamiri P. Immunobiology and privilege of neuronal retinal and pigment epithelium transplants. *Vision Res*. 2002;42: 487-495.
  161. Penfold P, Provis J, Furby J, Gatenby P, Billson F. Autoantibodies to retinal astrocytes associated with age-related macular degeneration. *Graefes Arch Clin Exp Ophthalmol*. 1990;228:270-274.
  162. Guerne D, Tso M, Edward D, Ripps H. Antiretinal antibodies in serum of patients with age-related macular degeneration. *Ophthalmology*. 1991;98:602-607.
  163. Akiyama H, Barger S, Barnum S, et al. Inflammation and Alzheimer's disease. *Neurobiol Aging*. 2000;21:383-421.
  164. Johnson LV, Leitner WP, Rivest AJ, Staples MK, Radeke MJ, Anderson DH. The Alzheimer's Aβ-peptide is deposited at sites of complement activation in patho-

- logic deposits associated with aging and age-related macular degeneration. *Proc Natl Acad Sci U S A*. 2002;99:11830-11835.
165. Ishibashi T, Miki K, Sorgente N, Patterson R, Ryan SJ. Effects of intravitreal administration of steroids on experimental subretinal neovascularization in the subhuman primate. *Arch Ophthalmol*. 1985;103:708-711.
  166. Nauck M, Karakiulakis G, Perruchoud AP, Papakonstantinou E, Roth M. Corticosteroids inhibit the expression of the vascular endothelial growth factor gene in human vascular smooth muscle cells. *Eur J Pharmacol*. 1998;341:309-315.
  167. Penfold PL, Wen L, Madigan MC, Gillies MC, King NJC, Provis JM. Triamcinolone acetonide modulates the permeability and intercellular adhesion molecule-1 (ICAM-1) expression of the ECV304 cell line: implications for macular degeneration. *Clin Exp Immunol*. 2000;121:1-9.
  168. Einer SG, Pavilack MA, Todd RF, et al. Modulation and function of intracellular adhesion molecule-1 (CD54) on human retinal epithelial cells. *Lab Invest*. 1992;66:200-211.
  169. Duguid IG, Boyd AW, Mandel TE. Adhesion molecules are expressed in the human retina and choroid. *Curr Eye Res*. 1992;11:153-159.
  170. Feeney-Burns L, Ellersieck MR. Age-related changes in the ultrastructure of Bruch's membrane. *Am J Ophthalmol*. 1985;100:686-697.
  171. Rungger-Brandle E, Englert U, Leuenberger PM. Exocytic clearing of degraded membrane material from pigment epithelial cells in frog retina. *Invest Ophthalmol Vis Sci*. 1987;28:2026-2037.
  172. Burns RP, Feeney-Burns L. Clinicomorphologic correlations of drusen and Bruch's membrane. *Trans Am Ophthalmol Soc*. 1980;78:206-223.
  173. Sarks JP, Sarks SH, Killingsworth MC. Evolution of soft drusen in age-related macular degeneration. *Eye*. 1994;8:269-283.
  174. Bressler NM, Silva JC, Bressler SB, Fine SL, Green WR. Clinicopathologic correlation of drusen and retinal pigment epithelial abnormalities in age-related macular degeneration. *Retina*. 1994;14:130-142.
  175. Abdelsalam A, Del Priore L, Zarbin MA. Drusen in age-related macular degeneration: pathogenesis, natural course, and laser photocoagulation-induced regression. *Surv Ophthalmol*. 1999;44:1-29.
  176. Mullins RF, Russell SR, Anderson DH, Hageman GS. Drusen associated with aging and age-related macular degeneration contain proteins common to extracellular deposits associated with atherosclerosis, elastosis, amyloidosis, and dense deposit disease. *FASEB J*. 2000;14:835-846.
  177. Haimovici R, Gantz DL, Rumelt S, Freddo TF, Small DM. The lipid composition of drusen, Bruch's membrane, and sclera by hot stage polarizing light microscopy. *Invest Ophthalmol Vis Sci*. 2001;42:1592-1599.
  178. Sarks SH, Arnold JJ, Killingsworth MC, Sarks JP. Early drusen formation in the normal and aging eye and their relation to age-related maculopathy: a clinicopathological study. *Br J Ophthalmol*. 1999;83:358-368.
  179. Sarks SH. Drusen patterns predisposing to geographic atrophy of the retinal pigment epithelium. *Aust J Ophthalmol*. 1982;10:91-97.
  180. Mullins RF, Johnson LV, Anderson DH, Hageman GS. Characterization of drusen-associated glycoconjugates. *Ophthalmology*. 1997;104:288-294.
  181. Marmorstein AD, Marmorstein LY, Sakaguchi H, Hollyfield JG. Spectral profiling of autofluorescence associated with lipofuscin, Bruch's membrane, and sub-RPE deposits in normal and AMD eyes. *Invest Ophthalmol Vis Sci*. 2002;43:2435-2441.
  182. Malek G, Li C-M, Guidry C, Medeiros NE, Curcio CA. Apolipoprotein B in cholesterol-containing drusen and basal deposits of human eyes with age-related maculopathy. *Am J Pathol*. 2003;162:413-425.
  183. Friedman E, Smith TR, Kuwabara T. Senile choroidal vascular patterns and drusen. *Arch Ophthalmol*. 1963;69:220-330.
  184. Tso MOM. Pathogenetic features of aging macular degeneration. *Ophthalmology*. 1985;92:628-635.
  185. Noji Y, Kajinami K, Kawashiri MA, et al. Circulating matrix metalloproteinases and their inhibitors in premature coronary atherosclerosis. *Clin Chem Lab Med*. 2001;39:380-384.
  186. Leu ST, Batni S, Radeke MJ, Johnson LV, Anderson DH, Clegg DO. Drusen are cold spots for proteolysis: expression of matrix metalloproteinases and their tissue inhibitor proteins in age-related macular degeneration. *Exp Eye Res*. 2002;74:141-154.
  187. Farboud B, Aotaki-Keen A, Miyata T, Hjelmeland LM, Handa JT. Development of a polyclonal antibody with broad epitope specificity for advanced glycation end products and localization of these epitopes in Bruch's membrane of the ageing eye. *Mol Vis*. 1999;5:11.
  188. Pauleikhoff D, Spital G, Radermacher M, Brumm GA, Lommatzsch A, Bird AC. A fluorescein and indocyanine green angiographic study of choriocapillaris in age-related macular disease. *Arch Ophthalmol*. 1999;117:1353-1358.
  189. Chen JC, Fitzke FW, Pauleikhoff D, Bird AC. Functional loss in age-related Bruch's membrane change with choroidal perfusion defect. *Invest Ophthalmol Vis Sci*. 1992;33:334-340.
  190. Remulla JF, Gaudio AR, Miller S, Sandberg MA. Foveal electroretinograms and choroidal perfusion characteristics in fellow eyes of patients with unilateral neovascular age-related macular degeneration. *Br J Ophthalmol*. 1995;79:558-561.
  191. Lopez PF, Sippy BD, Lambert HM, Thach AB, Hinton DR. Transdifferentiated retinal pigment epithelial cells are immunoreactive for vascular endothelial growth factor in surgically excised age-related macular degeneration-related choroidal neovascular membranes. *Invest Ophthalmol Vis Sci*. 1996;37:855-868.
  192. Frank RN. Growth factors in age-related macular degeneration: pathogenic and therapeutic implications. *Ophthalmic Res*. 1997;29:341-353.
  193. Kvanta A, Algere P, Berglin L, Seregard S. Subfoveal fibrovascular membranes in age-related macular degeneration express vascular endothelial growth factor. *Invest Ophthalmol Vis Sci*. 1996;37:1929-1934.
  194. Sarks JP, Sarks SH, Killingsworth MC. Morphology of early choroidal neovascularisation in age-related macular degeneration: correlation with activity. *Eye*. 1997;11:515-522.
  195. Nasir M, Sugino I, Zarbin MA. Decreased choriocapillaris perfusion following surgical excision of choroidal neovascular membranes in age-related macular degeneration. *Br J Ophthalmol*. 1997;81:481-489.
  196. McLeod DS, Luty GA. High-resolution histologic analysis of the human choroidal vasculature. *Invest Ophthalmol Vis Sci*. 1994;35:3799-3811.
  197. Chen SJ, Cheng CY, Lee AF, et al. Pulsatile ocular blood flow in asymmetric exudative age-related macular degeneration. *Br J Ophthalmol*. 2001;85:1411-1415.
  198. Kaplan HJ, Leibole MA, Tezel T, Ferguson TA. Fas ligand (CD95 ligand) controls angiogenesis beneath the retina. *Nat Med*. 1999;5:292-297.
  199. Kim I, Ryan AM, Rohan R, et al. Constitutive expression of VEGF, VEGFR-1, and VEGFR-2 in normal eyes. *Invest Ophthalmol Vis Sci*. 1999;40:2115-2121.
  200. Kliffen M, Sharma HS, Mooy CM, Kerkvliet S, de Jong PT. Increased expression of angiogenic growth factors in age-related maculopathy. *Br J Ophthalmol*. 1997;81:154-162.
  201. Wells JA, Murthy R, Chibber R, et al. Levels of vascular endothelial growth factor are elevated in the vitreous of patients with subretinal neovascularization. *Br J Ophthalmol*. 1996;80:363-366.
  202. Lip P-L, Blann AD, Hope-Ross M, Gibson JM, Lip GYH. Age-related macular degeneration is associated with increased vascular endothelial growth factor, hemorheology and endothelial dysfunction. *Ophthalmology*. 2001;108:705-710.
  203. Krzystolik MG, Afshari MA, Adamis AP, et al. Prevention of experimental choroidal neovascularization with intravitreal anti-vascular endothelial growth factor antibody fragment. *Arch Ophthalmol*. 2002;120:338-346.
  204. Seo M-S, Kwak N, Ozaki H, et al. Dramatic inhibition of retinal and choroidal neovascularization by oral administration of a kinase inhibitor. *Am J Pathol*. 1999;154:1743-1753.
  205. Schwesinger C, Yee C, Rohan RM, et al. Intrachoroidal neovascularization in transgenic mice overexpressing vascular endothelial growth factor in the retinal pigment epithelium. *Am J Pathol*. 2001;158:1161-1172.
  206. Spilisbury C, Garrett KL, Shen WY, Constable IJ, Rakoczy PE. Overexpression of vascular endothelial growth factor (VEGF) in the retinal pigment epithelium leads to development of choroidal neovascularization. *Am J Pathol*. 2000;157:135-144.
  207. Tombran-Tink J, Johnson LV. Neuronal differentiation of retinoblastoma cells induced by medium conditioned by human RPE cells. *Invest Ophthalmol Vis Sci*. 1989;30:1700-1707.
  208. Dawson DW, Volpert OV, Gillis P, et al. Pigment epithelium-derived factor: a potent inhibitor of angiogenesis. *Science*. 1999;285:245-248.
  209. Ohno-Matsui K, Morita I, Tombran-Tink J, et al. Novel mechanism for age-related macular degeneration: an equilibrium shift between the angiogenesis factors VEGF and PEDF. *J Cell Physiol*. 2001;189:323-333.
  210. Mori K, Gehlbach P, Yamamoto S, et al. AAV-mediated gene transfer of pigment epithelium-derived factor inhibits choroidal neovascularization. *Invest Ophthalmol Vis Sci*. 2002;43:1994-2000.
  211. Mori K, Gehlbach P, Ando A, McVey D, Wei L, Campochiaro PA. Regression of ocular neovascularization in response to increased expression of pigment epithelium-derived factor. *Invest Ophthalmol Vis Sci*. 2002;43:2428-2434.
  212. Sato TN, Tozawa Y, Deutsch U, et al. Distinct roles of the receptor tyrosine kinases Tie-1 and Tie-2 in blood vessel formation. *Nature*. 1995;376:70-74.
  213. Maisonpierre PC, Suri C, Jones PF, et al. Angiopoietin-2, a natural antagonist for Tie2 that disrupts in vivo angiogenesis. *Science*. 1997;277:55-60.
  214. Hanahan D. Signaling vascular morphogenesis and maintenance. *Science*. 1997;277:48-50.
  215. Hangai M, Murata T, Miyawaki N, et al. Angiopoietin-1 upregulation by vascular endothelial growth factor in human retinal pigment epithelial cells. *Invest Ophthalmol Vis Sci*. 2001;42:1617-1625.
  216. Otani A, Takagi H, Oh H, Koyama S, Matsumura M, Honda Y. Expressions of angiopoietins and Tie2 in human choroidal neovascular membranes. *Invest Ophthalmol Vis Sci*. 1999;40:1912-1920.

217. Oh H, Takagi H, Suzuma K, Otani A, Honda Y. Vascular endothelial growth factor (VEGF) and hypoxia regulate angiopoietin2 expression in retinal vascular endothelial cells. *J Biol Chem*. 1999;274:15732-15739.
218. Ahmed J, Braun RD, Dunn RJ, Linsenmeier RA. Oxygen distribution in the macaque retina. *Invest Ophthalmol Vis Sci*. 1993;34:516-521.
219. Campochiaro PA, Soloway P, Ryan SJ, Miller JW. The pathogenesis of choroidal neovascularization in patients with age-related macular degeneration. *Mol Vis*. 1999;5:34-38.
220. Mousa SA, Lorelli W, Campochiaro PA. Role of hypoxia and extracellular matrix-integrin binding in the modulation of angiogenic growth factor secretion by retinal pigmented epithelial cells. *J Cell Biochem*. 1999;74:135-143.
221. Lu M, Kuroki M, Amano S, et al. Advanced glycation end products increase retinal vascular endothelial growth factor expression. *J Clin Invest*. 1998;101:1219-1224.
222. Asahara T, Chen D, Takahashi T, et al. Tie2 receptor ligands, angiopoietin-1 and angiopoietin-2, modulate VEGF-induced postnatal neovascularization. *Circ Res*. 1998;83:233-240.
223. Murata T, He S, Hangai M, et al. Peroxisome proliferator-activated receptor- $\gamma$  ligands inhibit choroidal neovascularization. *Invest Ophthalmol Vis Sci*. 2000;41:2309-2317.
224. Sipes E, Tamargo R, Weingart J, Brem H. Inhibition of tumor angiogenesis. *Ann N Y Acad Sci*. 1994;732:263-272.
225. Taraboletti G, Garofalo A, Belotti D. Inhibition of angiogenesis and murine hemangioma growth by Batimastat, a synthetic inhibitor of matrix metalloproteinases. *J Natl Cancer Inst*. 1995;87:293-298.
226. Steen B, Sejersen S, Berglin L, Seregard S, Kvanta A. Matrix metalloproteinases and metalloproteinase inhibitors in choroidal neovascular membranes. *Invest Ophthalmol Vis Sci*. 1998;39:2194-2200.
227. Kvanta A, Shen WY, Sarman S, Seregard S, Steen B, Rakoczy E. Matrix metalloproteinases (MMP) expression in experimental choroidal neovascularization. *Curr Eye Res*. 2000;21:684-690.
228. Grunwald J, Hariprasad S, DuPont J, et al. Foveolar choroidal blood flow in age-related macular degeneration. *Invest Ophthalmol Vis Sci*. 1998;39:385-390.
229. Ciulla TA, Harris A, Chung HS, et al. Color Doppler imaging reveals reduced ocular blood flow velocities in nonexudative age-related macular degeneration. *Am J Ophthalmol*. 1999;128:75-80.
230. Ciulla TA, Harris A, Kagemann L, et al. Choroidal perfusion perturbations in non-neovascular age-related macular degeneration. *Br J Ophthalmol*. 2002;86:209-213.
231. Sarks JP, Sarks SH, Killingsworth MC. Evolution of geographic atrophy of the retinal pigment epithelium. *Eye*. 1988;2:552-577.
232. Sunness JS. The natural history of geographic atrophy, the advanced atrophic form of age-related macular degeneration. *Mol Vis*. 1999;5:25-30.
233. Holz FG, Bellman C, Staudt S, Schutt F, Volcker HE. Fundus autofluorescence and development of geographic atrophy in age-related macular degeneration. *Invest Ophthalmol Vis Sci*. 2001;42:1051-1056.
234. Gass JD. Drusen and disciform macular detachment and degeneration. *Arch Ophthalmol*. 1973;90:206-217.
235. Schatz H, McDonald HR. Atrophic macular degeneration: rate of spread of geographic atrophy and visual loss. *Ophthalmology*. 1989;96:1541-1551.
236. Weiter JJ, Delori F, Dorey CK. Central sparing in annular macular degeneration. *Am J Ophthalmol*. 1988;106:286-292.
237. Sunness JS, Gonzalez-Baron J, Bressler NM, Hawkins B, Applegate CA. The development of choroidal neovascularization in eyes with the geographic atrophy form of age-related macular degeneration. *Ophthalmology*. 1999;106:910-919.
238. Yates JRW, Moore AT. Genetic susceptibility to age-related macular degeneration. *J Med Genet*. 2000;37:83-87.
239. Seddon JM, Ajani UA, Mitchell BD. Familial aggregation of age-related maculopathy. *Am J Ophthalmol*. 1997;123:199-206.
240. Hammond CCJ, Webster AR, Snieder H, Bird AC, Gilbert CE, Spector T. Genetic influence on early age-related maculopathy: a twin study. *Ophthalmology*. 2002;109:730-736.
241. Stone EM, Sheffield VC, Hageman GS. Molecular genetics of age-related macular degeneration. *Hum Mol Genet*. 2001;10:2285-2292.
242. Kuntz CA, Jacobson SG, Cideciyan AV, et al. Subretinal pigment epithelial deposits in a dominant late-onset retinal degeneration. *Invest Ophthalmol Vis Sci*. 1996;37:1772-1782.
243. Piguet B, Heon E, Munier FL, et al. Full characterization of the maculopathy associated with an Arg-172-Trp mutation in the RDS/peripherin gene. *Ophthalmic Genet*. 1996;17:175-186.
244. Stone EM, Lotery AJ, Munier FL, et al. A single EFEMP1 mutation associated with both Malattia Leventinese and Drayton honeycomb retinal dystrophy. *Nat Genet*. 1999;22:199-202.
245. Allikmets R, Shroyer NF, Singh N, et al. Mutation of the Stargardt disease gene (ABCR) in age-related macular degeneration. *Science*. 1997;277:1765-1766.
246. Stone EM, Webster AR, Vandenburgh K, et al. Allelic variation in ABCR associated with Stargardt disease but not age-related macular degeneration. *Nat Genet*. 1998;20:328-329.
247. De la Paz MA, Pericak-Vance MA, Lennon F, Hames JL, Seddon JM. Exclusion of TIMP-3 as a candidate locus in age-related macular degeneration. *Invest Ophthalmol Vis Sci*. 1997;38:1060-1064.
248. Felber U, Doepner D, Schneider U, Zrenner E, Weber BH. Evaluation of the gene encoding the tissue inhibitor of metalloproteinases-3 in various maculopathies. *Invest Ophthalmol Vis Sci*. 1998;39:1054-1059.
249. Starita C, Hussain AA, Marshall J. Decreasing hydraulic conductivity of Bruch's membrane: relevance to photoreceptor survival and lipofuscinoses. *Am J Med Genet*. 1995;57:235-237.
250. Bohr VA, Dianov G, Balajee A, May A, Orren DK. DNA repair and transcription in human premature aging disorders. *J Invest Dermatol Symp Proc*. 1998;3:11-13.
251. Robert L, Peterszegi G. Aging and matrix biology. *Pathol Biol (Paris)*. 1998;46:491-495.
252. Munch G, Schinzel R, Loske C, et al. Alzheimer's disease: synergistic effects of glucose deficit, oxidative stress and advanced glycation end products. *J Neural Transm*. 1998;105:439-461.
253. Ambati J, Anand A, Fernandez S, et al. An animal model of age-related macular degeneration in senescent Ccl-2- or Ccr-2-deficient mice. *Nat Med*. 2003;9:1390-1397.
254. Ye SQ, Usher DC, Zhang LQ. Gene expression profiling of human diseases by serial analysis of gene expression. *J Biomed Sci*. 2002;9:384-394.
255. Lanchoney DM, Maguire MG, Fine SL. A model of the incidence and consequences of choroidal neovascularization secondary to age-related macular degeneration: comparative effects of current treatment and potential prophylaxis on visual outcomes in high-risk patients. *Arch Ophthalmol*. 1998;116:1045-1052.
256. Nelson KC, Carlson J, Newman ML, et al. Effect of dietary inducer dimethylfumarate on glutathione in cultured human retinal pigment epithelial cells. *Invest Ophthalmol Vis Sci*. 1999;40:1927-1935.
257. Benson AB III, Olopade OI, Ratain MJ, et al. Chronic daily low dose of 4-methyl-5-(2-pyrazinyl)-1,2-dithiole-3-thione (Oltipraz) in patients with previously resected colon polyps and first degree female relatives of breast cancer patients. *Clin Cancer Res*. 2000;6:3870-3877.
258. Ahir A, Guo L, Hussain AA, Marshall J. Expression of metalloproteinases from human retinal pigment epithelial cells and their effects on the hydraulic conductivity of Bruch's membrane. *Invest Ophthalmol Vis Sci*. 2002;43:458-465.
259. Sundelin SP, Nilsson SE. Lipofuscin formation in retinal pigment epithelial cells is reduced by antioxidants. *Free Radic Biol Med*. 2001;31:217-225.
260. Dylewski DP, Nandy S, Nandy K. Effects of centroproxone on lipofuscin in the retinal pigment epithelium of old mice. *Neurobiol Aging*. 1983;4:89-95.
261. Rasmussen H, Chu KW, Campochiaro P, et al. Clinical protocol: an open-label, phase I, single administration, dose-escalation study of ADGVPEDF.11D (ADPEDF) in neovascular age-related macular degeneration (AMD). *Hum Gene Ther*. 2001;12:2029-2032.
262. EyeTech Study Group. Anti-vascular endothelial growth factor therapy for subfoveal choroidal neovascularization secondary to age-related macular degeneration. *Ophthalmology*. 2003;110:979-986.
263. Ranson NT, Danis RP, Ciulla TA, Pratt L. Intravitreal triamcinolone in subfoveal recurrence of choroidal neovascularisation after laser treatment in macular degeneration. *Br J Ophthalmol*. 2002;86:527-529.
264. Takahashi T, Nakamura T, Hayashi A, et al. Inhibition of experimental choroidal neovascularization by overexpression of tissue inhibitor of metalloproteinases-3 in retinal pigment epithelium cells. *Am J Ophthalmol*. 2000;130:774-781.
265. Krzystolik MG, Afshari MA, Adamis AP, et al. Prevention of experimental choroidal neovascularization with intravitreal anti-vascular endothelial growth factor antibody fragment. *Arch Ophthalmol*. 2002;120:338-346.
266. Hangai M, Moon YS, Kitaya N, et al. Systemically expressed soluble Tie2 inhibits intraocular neovascularization. *Hum Gene Ther*. 2001;12:1311-1321.
267. Zarbin MA, Sugino IK, Castellarin A. RPE transplantation for age-related macular degeneration. In: Fine S, Berger J, Maguire M, eds. *Age-Related Macular Degeneration*. Philadelphia, Pa: Mosby-Year Book Inc; 1999:363-382.
268. Benner JD, Sunness JS, Ziegler MD, Soltanian J. Limited macular translocation for atrophic maculopathy. *Arch Ophthalmol*. 2002;120:586-591.
269. Del Priore LV, Kaplan HJ, Tezel TH, Hayashi N, Berger AS, Green WR. Retinal pigment epithelial cell transplantation after subfoveal membranectomy in age-related macular degeneration: clinicopathologic correlation. *Am J Ophthalmol*. 2001;131:472-480.
270. LaVail MM, Yasumura D, Matthes MT, et al. Protection of mouse photoreceptors by survival factors in retinal degenerations. *Invest Ophthalmol Vis Sci*. 1998;39:592-602.